
Canadian In-Training Vascular Surgery Oral Exams

Unofficial 2008 Review Notes
University of Ottawa
Anton Sharapov, MD

Updated May 21, 2009

What follows, is a collection of notes gleaned from the multitude of scraps, scribbles, summaries of texts (primarily Rutherford and Moore), and in-training written exams in Ottawa. Originally I started writing things down in preparation for my Canadian and American Vascular Boards. I did not find a unified editable collection of review notes anywhere, hence I decided to do this project.

These notes are FAR from being comprehensive. Also, being a huge fan of “Made Ridiculously Simple” series and “Whatever for Idiot’s” franchise (more by necessity, rather than by choice), I may have oversimplified things a bit to make it easier to understand and memorize. So consider information critically.

This is a composite body of work spanning several years of study notes written by the Canadian Vascular surgery fellows and which were passed on to the next generation. I edited these and added a few of impressions & biases of mine own. My study partners **Wesam Abuznadah, MD**, a fellow at U of Calgary and **Hao Ming Wu**, fellow at U of British Columbia, were instrumental with several revisions of the draft. Our thanks go to the generations of scribblers and note takers, to the “Big R”, as well as to our staff surgeons. We formed a google study group, and conducted almost daily conference meetings over Skype which was helpful.

This is not a substitute for reading Rutherford or doing actual oral exams. I know of several successful vascular surgeons who never did read Rutherford from cover to cover but they are just plain brilliant and full of inhibited genius. So unless you are all that, read your “big R”. I did.

This is a work in progress. You can’t quote what’s written here as the statements contained herein may all be pronounced blasphemous 5 years down the road. However, this is loosely based on what’s expected to know on the written part of the Canadian Vascular Board. Feel free to email me at antonsharapov@yahoo.com with constructive criticism etc.

To navigate, press CTRL and click on the item in the Content.

Table of Contents

CVI & LYMPHEDEMA.....	10
1.Bilateral swollen limb - approach:.....	10
2.Unilateral chronically swollen limb, DD:.....	10
3.Pt with Chronic venous insufficiency: approach.....	10
4.Young male with venous ulcer:.....	17
5.Middle aged female, bilateral varicose veins. Left leg worse than right.	18
6.Young woman, grossly swollen leg post uneventful ortho surgery on her ankle.	20
7.Phlegmasia cerulean dollens in a cancer pt.....	21
8.Patient with swollen leg with obvious lymphedema:	21
VASCULAR ACCESS.....	25
9.70 yom, in from nephrology for consideration for dialysis access.	25
10.Cold hand after AVF creation:.....	27
11.Lady with 6 mm ptfe AVF brachia-basilic, hand is numb:.....	29
12. AV graft with acute post op arm swelling. Treatment and work up.	30
13.Loop graft in forearm. High venous pressures on dialysis.	30
14.Infected groin AVF graft for dialysis.	31
15.70 yof, had her multiple failed AVFs, autologous, no vein on arms. Options?	31
UPPER LIMB:.....	31
16.General approach to Upper limb complaints –	31
17.Young female secretary comes in with pain in R arm. Normal pulses.	34
18.Axillary vein thrombosis in young male. Management:.....	38
19.Young man with ischemic R 4th finger.....	41
20.65 yom with acute onset R upper limb pain, weakness and numbness.....	44
21.Lady with confirmed L subclavian steal. symptomatic. nil on hx.	45

22. Angio - case with innominate, subclavian and SFA/SMA/Brachial stenosis...	46
23. Young female with HTN on one arm, low pressure on the other.	46
24. Middle aged construction worker, numbness, pain, ulcer in 5th digit.	48
AORTA – Aortoiliac insufficiency:	48
25. In AIOD setting, always ask re:	48
26. Elderly male, severe b/l claudication, no other medical hx.	49
27. 65 yom, farmer, c/o of blue toes. Take it from there.	52
28. 65 yom, farmer, disabling claudication, half a block. Smoker, all other RF normal.	54
29. Limb of ABF is occluded on angio, acute limb ischemia.	56
30. Angio on a claudicant done - R CIA 3 cm occlusion. What next?	60
31. Angio - called to IR suite - 50% stenosis R CIA - no obvious calcification.	61
32. Angio - disabling claudicant with 30% lesion in prox CIA on AP.	62
33. Complete aortic occlusion on angio.	62
AORTA -ANEURYSM:	64
34. Questions you'd always ask when have an "AAA" situation:	64
35. Called from ER re: hypotensive pt with pulsatile mass. Take over.	65
36. Middle aged man, presents to ER with hypotension, and left flank pain.	69
37. 47 yof, comes in with flank and abdo pain. ER doc does CT – inflammatory AAA. Approach.	69
38. Horse shoe kidney and infrarenal AAA.	70
39. EVAR: discuss indications, criteria, follow up plan, endoleak management.	71
40. Type III leak in aneuryx graft placed several years ago. Management?	73
41. Cancer Renal cell carcinoma and 6cm AAA.	73
42. Large AAA and iliac occlusive disease.	73
43. Type III Thoracoabdominal aneurysm:	74

44. Type IV TAA, b/l renal a. stenosis (severe) in hypertensive 65 yom.	77
AORTIC DISSECTION.....	78
45. Classification and management of aortic dissections.....	78
46. Man came with sharp shifting sudden back pain. New onset. Management.....	80
AORTA – INFECTED ANEURYSMS, GRAFTS, ETC	82
47. Elderly female with sudden, severe CHF.	82
48. Infected ABF case.....	86
49. Patient with previous AAA graft repair. Has Upper GIB.	91
50. L groin mass and pain 5 years after ABF:.....	94
51. Young male after intra-arterial injection.	95
CAROTID STUFF:.....	97
52. 60 yom with L TIA. Unremarkable H&PE.....	97
53. How to interpret results of carotid US:.....	101
54. CEA: indications for symptomatic and asymptomatic pts.....	105
56. Post CEA neurological deficit:.....	114
57. Intraoperative thrombosis during CEA:.....	116
58. Hyperperfusion syndrome:.....	117
59. 80 yof, 80% asymptomatic carotid stenosis.	117
60. Pt had TIA, history and exam is negative, Duplex, CT- head normal.....	117
61. 55 yom smoker, TIA, 50-79% on duplex.....	119
62. 76 yom, asymptomatic bruit on L. Class 3 angina, ESRD on peritoneal dialysis.	120
63. A young lady presented with a mass in her neck.	121
64. Head and neck colleague asks for help in OR. 20 yof with neck mass:	122
65. 70 yof, asymptomatic 70% ICA stenosis and carotid tumor on follow-up.	124
66. 50 yof, L hemispheric TIA, 90 % L CCA stenosis at the aortic arch.	124

67. Occluded CCA with symptomatic (amaurosis fugax) ECA stenosis on angio.	124
68. Angio on pt with TIA: ICA is occluded but CCA and ECA are open, ECA stenosis.....	125
69. Combinations of carotid and coronary disease and approaches to both.	125
70. Describe horner's syndrome in carotid dissection.....	126
71. Causes of spontaneous carotid dissection.....	126
72. Describe dynamics of a steal phenomenon (vertebral a. steal)	127
PELVIC AND INFRAINGUINAL STUFF.....	128
73. Advantages and disadvantages of insitu vs reversed vein bypass.....	128
74. Describe different types of ulcers:.....	129
75. 60 yom, claudicant. Conservative management failed. Approach.	133
76. Claudicant in 50 yom:.....	138
77. Outline conducts of insitu bypass:.....	140
78. Post BK fem-pop in situ bypass for rest pain. Pt has recurrence of symptoms.....	142
79. 60 yom with acutely ischemic left leg. DDX and management:.....	144
80. 60 yom with sudden onset of bilateral painful lower extremities	151
81. When do you do thrombolysis in thrombosed popliteal artery aneurysm?.....	151
82. Patient with AF and chronic PVD. Numb/paralyzed foot for 3 hrs.	152
83. 50 yom, claudication on R: no pop pulse, large pulse in L pop fossa:.....	153
84. Diabetic foot with gangrenous toe:.....	154
85. 32 year old male, with retinal hemorrhage, CAD and b/l IC:.....	154
86. 35 year old male smoker with gangrenous 1st and 2nd toes:.....	155
87. 30 yom, short distance claudication:.....	156
88. Fever and chills 3/52 after R iliac stent. CT shows air around CIA.	157
89. General surgery resecting cecal tumor. Find the mesentery is attached to the R CIA..	157
90. Patient went for coronary angio. Develops ischemic leg post procedure.	158

91.R groin thrill on exam post cardiac catheter. Approach:.....	159
TRAUMA:.....	159
92.MVA and iliac artery injury.....	159
93. Middle aged female, MVA and aortic injury.....	161
94.Bike accident. Occluded distal axillary/proximal brachial artery (transected).....	162
95.Young male, MVA, Polytrauma, chest trauma.....	163
96.35 yom, MVA, fractured pelvis, ribs, R tib-fib. Asked to see re: ischemic R leg.....	166
97.40 yom construction worker, isolated knee dislocation, pulseless foot.	168
98.Called to ICU – placed 8 Fr sheath into R subclavian artery. Approach:.....	169
99.30 yom, 3 weeks post stabbing in the thigh. Pulsatile thigh mass.	170
MESENTERIC ISCHEMIA.....	170
100.75 yof, b/l claudication, CMI.....	170
101.70 yof, CMI, severe SMA/Celiac stenosis. Complication of PTA.....	178
102.55 yom, post mi requiring prolonged CPR. In ICU on pressors. Develops abdo pain.	178
103.Suspected SMA aneurysm:.....	179
RENOVASCULAR STUFF.....	180
104.AAA and RAS in 80 yom, well controlled HTN on 3 meds, Cr 130.	180
106.70 yom, smoker, HTN, on bblockers, Cr 150, 7 cm juxtarenal AAA.....	188
107.70 yom, good cardiac risk, 8 cm AAA, CR 160, poorly controlled HTN on 3 drugs....	189
108.80 yom, 2 antihypertensives, Cr 95, previous MI, stable angina. 6.5 cm AAA with RAS	189
109.80 yom, severe HTN on 3 drugs, difficult to control, 7 cm infrarenal AAA, Cr 300.....	190
110. Angio of renal a. aneurysm: distal, near the first branching, asymptomatic pt.	190
110.56 year old female, with HTN. Work-up shows 2.5 cm renal artery aneurysm.	191
111.45 yr old female with uncontrolled HTN. Approach.	191

CVI & LYMPHEDEMA

1. Bilateral swollen limb - approach:

Systemic cause - MC

Diffuse, bilateral

CHF – better in the morning after rest, but CHF may get worse

Renal – not better with resting/supine position

Lymphedema

Involves feet AND toes

Hence Squaring of toes

Long standing – causes stigmata

Fibrosis (becomes non-pitting)

keratosis

Drug induced

Adalat, mild

DVT – iliofemoral or ilio caval

Stigmata of CVI

The only condition to cause perimaleolar scarring

Phlegmasia cerulea alba -> dolens

Aorto-caval fistula

Fat legs

2. Unilateral chronically swollen limb, DD:

Lymphedema

CVI due to deep incompetence (secondary)

CVI due to proximal venous obstruction

Arterio-venous fistula (for dialysis)

Congenital malformation

Flare stage of complex regional pain syndrome

3. Pt with Chronic venous insufficiency: approach

History should always include:

- profession/long upright standing.
- Review previous ulcer/vein surgery/treatment
 - compliance and work up.
- history of vein harvest,
- DVT
- pregnancy,

- hypercoagulability,
- trauma
- avf

- hx of IC/rest pain
- RF for Atherosclerosis as the ulcers will turn out to be mixed in origin
 - smoking, htn, hl, homo, dm, cva/mi
- hospital admission

Aside:

Classify varicosities –

- congenital,
- primary (underlying structural problem),
- secondary

Distinguish primary from secondary varicosities:

Primary:

- early onset, fam hx of varicosities.
- Precipitating factors: after pregnancy, external compression (may thurner, pelvic mass).

Secondary:

- will have hx of normal limb, then DISTINCT event (DVT/trauma/iatrogenic procedure/surgery),
- hypercoagulable state/fam hx of such,
- contraceptive use,
- AV fistula.

On exam:

- With primary, likely see SFJ involvement only, i.e. predominantly superficial reflux
 - i.e. no perf/deep vein problems

less remarkable CVI stigmata.

Secondary will have more advanced disease

Deep reflow, perforators, significant CVI stigmata

inspect –

swelling, varix, ulcer - vein: pink, clean bottom, flush with skin level, moderately tender to touch, painless, better with elevation, bleeds on probing, gaiter area, normal pulses, signs of CVI

telangiectasia/reticular (1),
varicose (2),
swelling (3),
skin changes - atrophy blanche, lipodermatosclerosis (4),
healed ulcer (5),
active ulcer (6).

Aside:

Arterial ulcer - pale fibrinous necrotic bottom, distal foot, painful, punched out, poor pulses, better with dependency, signs of PAD and RF on history plus IC/rest pain.

Exam cont'd

auscultate: bruit for PAD

palpate: Trendelenberg, pulses

Assess reflux in superficial and deep system and perforators.

Trendelenberg test –

- supine, elevate leg, compress GSV junction or LSV junction.
- Stand up, maintain compression:
 - watch fast refilling of vein from below – check perforators
- Release compression –
 - see fast refilling from above – check in line valve insufficiency

Finally, investigations:

- Duplex

First check for DVT when supine, and > 2 sec reflux at SFJ with valsalva

Upright – check for >0.5 sec reflux with cuff deflation distal to SFJ

- Venography – rarely 1st line of investigation
 - Ascending for obstruction
 - Descending for reflux
 - Pressure gradient studies if suspect obstruction
- ABI +/- angio if necessary
- CT/MRI if suspect central obstruction

Ambulatory venous pressure:

- Pressure in the dorsal pedal vein after 10 consecutive calf contractions.
- Should dip from 80 mm Hg standing to 20-30 mm.
 - If going up – suspect proximal obstruction

- Should take 30 sec or more to return to 80 mm with standing quietly:
 - If faster – suspect valve incompetence

PPG and APG are non-invasive substitute for invasive AVP measurement.

Conservative treatment:

- Compression
- Dressing change – DRY gauze
- Elevation
- ASA/iodosorb/pentoxifylline/Prostoglandin
 - p. 2245-47
 - NO occlusive hydrocolloid dressings (duoderm)
 - same healing rates as dry, may be more infection

Compression: Rutherford: 30-40 mm Hg below knee
 Sigvaries recommends the following CI:

Absolute contraindications:

- Advanced peripheral obstructive arterial disease
- Severe neuropathy (diabetic)
- Congestive heart failure (active)
- Septic phlebitis
- Plegmasia coerulea dolens

- Unaboot – glycerin, zn oxide, chamomile, sorbitol, mg, al silicilate

If mixed ulcer in old gentleman and ABI 0.6 - may try light profore dressing for 3-4 weeks

If not improving - review diagnosis:

- r/o non-compliance
- mimickers:
 - CTD
 - HTN
 - Malignancy
 - Pyoderma gangrenosum
 - Calcifilaxis in dialysis patients
- local and general factors preventing healing:
 - infection
 - r/o osteomyeltis and w&w infections
 - ongoing trauma

- stalled wound
 - need for debridement,
 - needs growth factors
- malnutrition
- immunocompromised state
 - malnourished
 - cancer
 - chemo

Consider adjuncts -

- intermittent compression
- promogran/regrenex/platelet spin-off to kick start stalled wound
- abx iv/po if cellulitis
- antimicrobial in the wound
- consider hyperbaric oxygen
- consider apligraf/pentoxifylin, iloprost

If surgery necessary –

- consider location and see if stripping GSV/ligation would help.

Indication for surgical intervention: after 3 months of intensive compliant conservative management...

1. ulcer
2. pain
3. bleeding
4. superficial thrombophlebitis and thrombosis of GSV
5. cosmetic

- Perforator incompetence – after patient failed compression therapy AND proximal stripping/ligation - try SEPS vs open perforator ligation.

Indications for perforator ligation:

1. have to have class 4 and above....
 - Lipodermatosclerosis and atrophy
2. Failure of conservative tx of severe stasis symptoms
3. Recurrent cellulitis/recurrent DVT during conservative treatment
4. Relative – non-compliance with conservative

Contraindications to perforator ligation:

1. Chronic PAD
2. Infected ulcer

3. Morbid obesity
4. Non-ambulatory and high risk pt
5. Relative: CRF, DM, Rheumatoid arthritis

Results of perforator ligation:

- Difficult to distinguish between contribution of GSV L/S and perforator surgery
- ulcer healing at 10 y – 60%
 - long term recurrence 20% (40% in post thrombotic limbs)
- improved hemodynamics (Ambulatory Venous Pressure) in some but not all studies
- possible that sclerotherapy may be better than SEPS or surgery...

Surgery:

1. Subfacial Endoscopic Perforator Ligation (SEP)
2. Open – modified (for cocket I)
3. Open for the rest of them – modified Linton (not done much)

Results:	SEPS	Open
Ulcer Healing	94%	88%
Ulcer recurrence	11%	22%
Wournd complications	5%	24%

Hence, same healing, less recurrence, less wound complications

Sclerotherapy:

- Detergent – STD, STS, polydocanol (best, not approved in NA, local anesthetic)
- Corrosive- glycerol, iodine
- Hypertonic – mildest- hypertonic saline

After injecting vein (mix 1:4 with air in two syringes, make sure pts works the calf – get them to walk around your office (to prevent deep vein injury). Warn re: side effects – pulmonary embolism, angina, stroke... These are very RARE

Will need to drain sclerosant/thrombosed vein within 24 h, otherwise – pigmentation.

Describe venous system:

- deep, superficial, perforators, flow direction.

What moves venous blood:

- valves, calf/motion, gravity, effect of breathing, valsalva, intraabdominal pressure, diastolic pressure.

List LE perforators:

- Connect GSV and deep system
- Cockett I, II, III
 - go from posterior arch vein (NOT GSV) to post tibial vein
 - cockett 1 at med malleolus
 - along Linton's line: 6, 12, 18 cm from floor, 4 cm posterior to medial edge of tibia
- Paratibial perforators
 - 2 cm medial to the medial edge of tibia, go from GSV to posterior tib and pop vein
- Thigh:
 - Hunterian (H for high) – in the mid HIGH thigh
 - Dodd's (D for DISTAL for low thigh)
 - Boyd's (B for BELOW) – below knee
- Vein of Giacommi – connects GSV and LSV

What is the cause of Venous claudication:

- Definition: Bursting deep leg pain with exercise
- Proximal venous obstruction, distal veins are usually normal
- Due to exercise induced hyperemia AND increased resistance to venous outflow.

Chronic deep vein obstruction:

- Intrinsic venous defect:
 - Acute DVT
 - Endothelial scarring:
 - Post chronic DVT
 - Radiation
 - Abnormal venous webs, hypoplasia, aplasia
- External compression
 - Retroperitoneal fibrosis
 - Benign/malignant tumor
 - Cyst
 - Aneurysm (arterial)
 - Bands/slips
 - May Thurner syndrome (L common iliac vein compressed by R CIA)

Testing:

- Duplex
- Plethysmography
- CT/MRI abdomen
- Gradients:

- Resting arm/foot venous pressure difference > 4 mm Hg is abnormal
- Resting supine central/femoral pressure difference > 5 mm Hg is abnormal
- 2 fold increase in femoral pressure after exercise is abnormal
 - 10 dorsiflexions at ankles
 - 20 isometric calf contractions
- Venography – for OR planning
- Bypass – Palma procedure to bypass femoral/iliac occlusion
 - Swing GSV to the obstructed side, AVF to recipient end of the vein

Why bypasses for venous repair are prone to failure?

- Low flow due to
 - collateral circulation
 - distal venous obstruction
 - incompetent valves
- easily compressible grafts
 - due to low pressure in the circulatory system
 - dependence on intraabdominal/thoracic pressure
 - location behind inguinal lig/liver
- increased thrombogenicity
 - most pt have lack of pn C, S, AT III
 - synthetic grafts more thrombogenic

What can be done?

- Use Large diameter graft with external support
- Use Autogenous vein (tunnel it within PTFE ringed graft)
- Distal AVF (on the side that needs venous decompression)
- Periop/post op Anticoagulation
- Periop intermittent compression pump
- Post op surveillance with Duplex

4. Young male with venous ulcer:

Approach and work up

Management

Superficial incompetence only, N deep

Perforator incompetence.

Superficial thrombophlebitis extending to SFJ – management and why.

Approach:

Full hx and pe (see above)

Dd primary vs secondary

Stage for CEAP

Duplex – superficial, deep obstruction/competence

Canadian Vascular Surgery In-Training Cases, U of Ottawa, Anton Sharapov, MD, 2008

3/12 conservative – compression

If failed, review compliance/infection/diagnosis

Consider surgery – AK stripping & SFJ ligation vs EVLT/RFA

Stripping&ligation has lower recurrence compared to simple ligation.

If failed to heal – consider contribution of perforators

Review CI to perforator ligation

Offer SEPS in center of excellence vs sclerotherapy

If pt has clot at SFJ only

If encroaches into fem vein

Consider surgery (control CFV, milk out clot, ligate SFJ) vs AC

5. Middle aged female, bilateral varicose veins. Left leg worse than right.

Aching pain, some swelling. No ulcerations. No hx of DVT. Rest of history unremarkable.

Complete history:

Occupation, timing of varicosities, treatments, OCP/pregnancy/DVT/HCS

Physical exam findings in CVI?

ie. lipodermatosclerosis, atrophie blanche i.e. evidence of skin changes (C4)

- 1. Telagectasia, reticular veins, malelar flair
- 2. Varicose veins
- 3. Edema, no other changes
- 4. Skin changes – pigmentation, atrophy, lipodermatosclerosis
- 5. Skin changes + healed ulcers
- 6. Skin changes + active ulcers

with varicose and swelling alone, this would be C3

Investigations?

duplex

What do you want to look for on duplex?

<0.5 sec reflux standing

If air pletysmography – look for >30 ml/sec Venous Filling Index

Note, do not confuse Filling index (abnormal >30 ml PER second) with Filling time – (normal > 30 sec)

What is a contraindication to superficial venous stripping?

Deep vein DVT

Decided on trial of conservative management with compression stockings. What is amount of compression? knee vs thigh high?, how often to change? etc.

Change as needed, every 3-6/12

Knee high, 30-40

Appropriate ulcer tx

r/o contraindications to compression, infections, stalled wound

Failed conservative tx. Next?

Review compliance, diagnosis, infections, stalled wound, duplex (reflux and perf)

On DUS - No deep venous insufficiency or DVT. Bilateral GSV incompetence.

Surgery versus ELVT? Evidence for EVLT?

Surgery shown equivalent to RFA

No comparison for EVLT vs surgery

RFA shown superior to EVLT in RCT

What kind of surgery?

GSV ligation AND above knee stripping

Less recurrence compared to just ligation

Below knee stab avulsion

Strip below the knee? NO. Why not?

Injury to saphenous n

What about sclerotherapy?

For smaller varicosities

- Patient comes back before her surgery with superficial thrombophlebitis. Management?

r/o septic thrombophlebitis

ensure SFJ is patent

warm compresses, asa

- Duplex shows thrombosis just into the CFV. TX?
 - anticoagulate if no contraindication.
 - Consider ligation and clot extraction

Notes re: EVL

<http://www.nice.org.uk/nicemedia/pdf/ip/132overview.pdf>

Rautio et al. Endovenous obliteration versus conventional stripping operation in the treatment of primary varicose veins: A randomized controlled trial with comparison of the costs. *Journal of Vascular Surgery* 2002;35(5):958-965.

[J Vasc Surg.](#) 2003 Aug;38(2):207-14.

- EVLT was noted to be less effective than RF in one RCT according to Rutherford
- Surgery vs EVLT – no RCT
- Surgery vs RF - RCT
 - EVOLVES study
 - The 2-year clinical results are at least equal to those after high ligation and stripping of the GSV.
 - Recurrence and neovascularisation rates were similar in the two groups
 - limited patient numbers prevent reliable statistical analysis.
 - Improved quality of life scores persisted through the 2-year observations in the RFO group compared to the S and L group.
 - Less pain, earlier to work, comparable recurrence of 7% at 2 years

- Avoid EVLT for vein under skin, venous aneurysm within 2 cm of SFJ, and very large varix.

6. Young woman, grossly swollen leg post uneventful ortho surgery on her ankle.

Swelling from the foot to the groin, the lower leg is cyanotic with blisters on the calf; the muscle compartments are tender with compression, reduced sensation in the foot. Distal pulses are palpable. A duplex venous scan confirms the diagnosis of an iliofemoral venous thrombosis. Clinically you are concerned about the viability of the leg.

- Discuss your management of this patient.
- If you feel that surgery is indicated, describe the technique

Answer:

- Phlegmasia cerulea dolens case
 - i.e. I think all venous outflow is occluded
 - for alba dolens – some venous collaterals are still open
- Review contraindications for anticoagulation & Start iv heparin
 - Uncontrolled HTN
 - Recent GI/GU bleed
 - Frequent falls (more for longterm)
 - Inability to monitor therapy (more for long term)
- No role for CDT here
- Pts will need immediate decompression of the venous outflow obstruction
- Will need thrombectomy/AVF/AC
 - Initially Thrombectomy forsaken after POORLY analysed Lansing's paper
 - Resurgence in 1970's
 - Shown patency of thrombectomized vein is high
 - Re-analysis of the Lansing paper was more favorable
- Conduct of thrombectomy: p. 2192
 - Heparin preop
 - Cavagraphy first to establish extent of clot
 - Retrievable IVC filter from neck or Normal CL side first
 - Obtain consent, abx, angio table, C-arm, xmatch, blood in room, help
 - Fasciotomy 1st if phlegmasia cerulea dolens
 - For immediate improvement of circulation
 - Dissect groin, CFV, CFA, SFJ
 - Ask anesthesia to increase PEEP during venous manipulations
 - If awake, ask pt to do Valsalva during clot extraction
 - Longitudinal venotomy
 - According to Rutherford

- If need be, can extend distally to explore profunda vein
- Proximal vena cava Fogarty
- Apply distal eschmark
 - Squeeze clot “toothpaste technique” out of distal leg
- Close venotomy
 - If CAN’T extract clot from femoral vein, ligate CFV
- Completion IVC venogram – assess for stenosis/need for PTA/stent
 - Need large venous pigtail
- AVF with BRANCH of GSV
 - close it with coil, open, pull up stitch placed around the branch etc..
- anticoagulate post op, consider need for long term anticoagulation

7. Phlegmasia cerulean dollens in a cancer pt.

Assess pt status – confirm limb threatening situation
end-stage palliation vs remission vs stable palliative

Assess premorbid functional status

Find out cause – hypercoagulable state vs mechanical obstruction

Retroperitoneal compression

Matted Lymphnodes

Mass/tumor

Post central line scarring

Assess pts RF for thrombectomy

If reasonable life expectancy and premorbid functional status, AND you predict there is good chance of relieving venous obstruction (i.e. no tumor compression etc) , take to OR for thrombectomy

Otherwise – consider AC or CDT if not candidate for surgery

8. Patient with swollen leg with obvious lymphedema:

differential diagnosis,
work-up,
treatment,
surgical options

DD:

- Acute:
 - Acute limb ischemia
 - Cellulites

- DVT
- Trauma
- Fracture
- Torn ligament/muscle
- Ruptured Baker's cyst

- Chronic
 - AV malformation
 - Lymphedema
 - CVI
 - Systemic disease
 - CHF
 - CRF
 - Low protein
 - Liver failure
 - Nephrotic syndrome
 - Reflex sympathetic dystrophy (acute stage)
 - fat

Etiologic classification:

- Primary:
 - Congenital ≤ 1 yoa
 - Non-familial
 - Familal (Milroy) – **Roy** - King by birth
 - Praecox 1-35 yoa
 - Non-familial
 - Familial (Meig) – got my first **Mig** 35 precociously before 35 yoa
 - Tarda > 35 yoa
 - **Ta-DA!** I am old now...
- Secondary:
 - Filariasis
 - Lymph node/vessel injury:
 - Surgery – MC in NA – post mastectomy
 - infection
 - tumor
 - rads
 - trauma

Anatomic classification:

	Distal hypoplastic 80%	Proximal hypoplastic 10%	Hyperplastic 10%
--	------------------------	--------------------------	------------------

Gender distribution	females	Any gender	Any gender
Laterality	bilateral	unilateral	Bilateral
onset	At puberty	Any age	Congenital
Fam hx	positive	No	Positive
progression	Benign, slow course	Fast progression	Progressive
Response to TX	Well to conservative tx	Poor to conservative tx **	Responds to conservative tx ***

- ** proximal hypoplastic – May be candidates for microvascular reconstruction
- *** hyperplastic
 - mesenteric lymphatics is incompetent –
 - reflux of chyle and pn losing enteropathy.
 - Chylous drainage via vagina, scrotum, lower extremities.
 - May be treated with retroperitoneal excision of incompetent lymphatics.

On history:

1. Age of onset, family history, laterality to classify
2. Ascertain chronicity
3. Ask about surgeries
4. Ask about infections and travel history
5. Work up hx: CT/dye test
6. Ask about impairment of mobility
7. Treatments given/compliance
8. Ask about family hx
9. Swelling: painless vs painful

On exam:

1. General exam: r/o CHF, vascular exam
2. Non-pitting edema
3. Hyperkeratosis/lichenification of skin – peau d’orange/verrucous changes
4. Small vesicles draining lymph
5. Squaring of toes
6. Stigmata of CVI and PVD

Lymphoscintigraphy:

Canadian Vascular Surgery In-Training Cases, U of Ottawa, Anton Sharapov, MD, 2008

Look for > 1h time for evacuation of dye
Look for peripheral/subdermal backflow

Long term complications of Lymphedema:

- Infection
- Fibrosis
- Neoplasia (lymphangiosarcoma, Stewart-Thrives)
- Malnutrition
- Immunodeficiency

Conservative treatment is maintstay:

- prevention/treatment of cellulitis
 - penicillin 500 mg TID at first sign of infection
- elevation & compression, manual decongestion
- benzopyrones
 - may be effective in reabsorption and mobilization of tissue pns

Surgical treatment of lymphedema

Indications:

- Failure of conservative methods
- Improvement of limb function: severe impairment of mobility
- Reduction of pain
- Cosmetic improvement
- Reduction of complications
 - cellulitis, lymphangitis, lymphangiosarcoma

Surgical options:

- excisional operations RARE
 - a. Charles – skin/fascia/tissue, then graft
 - b. Miller - staged subcutaneous excision beneath flaps
- microsurgical lymphatic reconstruction: V.RARE
 - a. lymphovenous anastomosis
 - b. lymphatic grafting
 - c. free lymphatic flap, omental transfer, adipovenoslymphatic transfer
- liposuction

VASCULAR ACCESS

9. 70 yom, in from nephrology for consideration for dialysis access.

Hx:

etiology of renal failure,
GFR (should be <30 ml/min)
plans for transplant,
current means of dialysis
perc lines, where, how long, complications

Technical considerations:

Hand dominance, paresthesias, hand weakness, arm swelling, superficial vein prominence, neck swelling, arm circulation problems.

RF for ASc, management of RF, MI/CVA,

Previous vein harvest, radial a. harvest (CABGE, PVD), hypercoagulable state.

ROS:

good shape?
SOB/CP
IC/rest pain/ulcer
need to know if harvesting GSV for later time
General suitability for surgical procedures

Pt is diabetic, no transplant, R IJ catheter, R hand dominant. No vein harvest.

Physical exam:

BP both arms (SCA stenosis),
arm-hand pulses/Allen/doppler signals
Veins survey with/without tourniquet
Swollen upper limb,
shoulder sc collaterals.
Signs of muscle wasting/uppe/lower limb ischemia.
General Vascular exam.

Vein mapping:

- Vein - Need 2.5 mm below elbow, 3 mm above
- Artery – at least 2 mm diameter
- Use tourniquet for vein mapping
- If vein > 5 mm deep, may need to superficialize it at the later date
- High radial a. take off may lead to steal in radiocephalic AVF

Exam ok, pt has good veins.

No need for further testing.

Duplex of central veins and superficial veins if suspect central vein occlusion
multiple punctures/cath
poor sup veins
chest vein prominence

Plan for AV access.

Usual preop:

CONSENT:

Patency info, complications (steal, neuropathy), need for revision

2 year patency, 1500 pt series:

secondary 60% for all,

primary:

autologous 40%

prosthetic 20%

Options?

Autologous

direct radio-C, brachi-C, transposition - radio/ulnar/brachio Basilic, translocation - forearm, GSV
if no PVD. As per DOQI recommendations

prosthetic

loop or straight from radial or brachial to deep brachial or axill vein.

Start on nondominant upper extremity distally, move to antecubital, then to axillary,
reluctantly go to lower extremity, then weird and wonderful (tunnelled cath to IVC...).

I recommend snuff box fistula at the non-dominant hand with no line on that side.

Ok, you go in, and at snuff box, vein does not look good...

I'll go to radio-cephalic, Brescia-Cimino AVF.

What is normal AVF flow?

- total AVF flows above 600 ml/min are enough for dialysis.
 - ideally, aim for a flow of ~1000 ml/min.
 - minimum flow required is 350 cc/min noted on 6 occasions/month
 - 2000 ml/min is too high.
- If an AVF flow falls by 25% or more in any given 4 months,

- AVF exam with ultrasound or a fistulogram.
- US Sign of mature vein
 - >4 mm diameter, >500 cc/min – 95% maturation certainty
 - <4 mm, <500cc/min – 33% maturation certainty

10. Cold hand after AVF creation:

7 days after construction, pt complains of cool hand, numbness all over, comes back.

on Hx, review her preop paresthesias (no, it's new thing).

On exam,

remeasure arm pressures (equal - looking for central arterial stenosis),

look at the hand - ischemic? (pale), radial pulse (weak),

effect of AVF compression on hand (pinks up a bit),

ulnar pulse? (present).

Evidence of Carpal tunnel (less likely)

Pt has reduced pulses...

I'll order duplex –

look for the ulnar circulation, palmar arch flow, reversed flow in the distal radial and in the arch that is normalized to antegrade flow with AVF compression.

i.e looking for evidence of steal.

You confirm your diagnosis of steal. Ulnar a. is normal. Next?

options –

ligate distal radial artery vs ligate fistula

I'd recommend distal radial a. ligation if ulnar a. is present and normal.

This, in essence would give her DRIL equivalent with ulnar a. acting as bypass...

Who is likely to develop steal?

diabetic, woman, brachi-cephalic access, uncommon with radial AVF...

unless pt has high take off of radial artery off brachial...

Say you have different scenario, with radio-cephalic AVF, and steal... Approach?

I'd interview and examine the pt looking for

evidence of subclavian stenosis,

distal ischemia,

effect of AVF compression,

neurologic deficit

Hand is ischemic, a bit better with AVF compression.

I'll do duplex and arteriogram (with AVF compression) including proximal imaging (subclavian a.)

ok, you get flow reversal, diseased radial and ulnar artery but ok interosseous a.,

Improvement of flow to hand after AVF compression? Yes. Then I'll offer DRIL.

What is it?

distal revasc, interval ligation:

bypass with proximal anastomosis above AVF, distal below, and ligation between distal anastomosis and AVF

This will increase resistance to reverse flow to the pressure sink area in the AVF area.

When would you not do DRIL?

If there is extensive disease in the vessels AND no improvement in circulation with fistula compression.

Aside, do not confuse regular steal with ischemic monomelic neuropathy – due to watershed aread steal of vasa nervorum in antecubital area. Starts immediately post surgery, requires emergent AVF take down. No obvious circulation abnormality.

Complications of access?

- Failure to mature
- Stenosis (particularly at the venous end)
- Aneurismal dilatation
- Bleeding that can lead to...
 - Pseudoaneurysm
- Seroma that can lead to ...
 - Infection
- Steal that can lead to:
 - Heart failure
 - Swelling and Venous hypertension
 - Neurophathy – monomelic neuropathy

How do you do transposition?

I explained.

2 stage vs 1 stage?

I'll do one stage, as per my training, even though there are purported benefits of saving pt the dissection of the vein if does not mature.

Canadian Vascular Surgery In-Training Cases, U of Ottawa, Anton Sharapov, MD, 2008

11. Lady with 6 mm ptfе AVF brachia-basilic, hand is numb:

Hx –

worse with dialysis.

no ulcer.

has rest pain. some numbness.

weak hand. non-dominant hand.

Nil else (no other RF for Asc, prev rads, CTD)

on exam –

no radial pulse, appears with occlusion of the AVF. no tissue loss.

plan:

first, r/o inflow problems – subclavian/innominate stenosis

doppler –

reversal of flow in brachial artery,

change in phasicity of flow in radial artery with AVF occlusion,

identify problems with proximal/distal AVF anastomosis.

Then angio to look for evidence of distal occlusive lesions in forearm.

Confirmed steal. What is steal?

preferential outflow to lower resistance network.

Usually worse in the conditions of reduced inflow

Plan:

she has rest pain, disabled. Hence, intervention:

Distal revascularisation, interval ligation (vein bypass from prox to Arterial AVF anastomosis to distal site, then ligate artery distally to the original Arterial AVF anastomosis).

If radiocephalic AVF and Normal Ulnar artery, ligate radial artery distal to AVF

A sort of DRIL procedure, with ulnar and palmar arch acting as a bypass

interpose tapered PTFE 4->7 mm graft instead of banding (4 mm to arterial side)

proximalization of inflow:

- for brachioceph AVF, move inflow to the axillary artery
 - increases inflow pressure
- makes it harder for reversal of flow in the brachial circuit

Distalization of inflow:

- for brachioceph AVF, move inflow distally to radial a.
- in a way, this is like controlled banding or creating a smaller diameter inflow

banding with OR PRV/plethysmography - look at the increase in wave forms amplitude on fingers while increasing banding - really is the last option short of ligation

take down fistula (ligate)

12. AV graft with acute post op arm swelling. Treatment and work up.

Venogram showed central venous thrombosis. Management.

Differentiate primary vs secondary thrombosis

This is one is likely due to stenosis in central veins: i.e. secondary

Ascertain status of AVF and provide alternate means of dialysis access

Counsel pt re: CDT vs take down of AVF followed by reassessment of symptoms

If symptomatic may still be stuck with an intervention

Review contraindications to thrombolysis

- Absolute
 - CVA event (including TIA) in past 2 months
 - Intracranial trauma (including neurosurgery) in past 3 months
 - active bleeding
 - GI bleed in past 10 days
- Relative major
 - Trauma & surgery:
 - major non-vascular trauma or surgery in past 10 days
 - CPR in past 10 days
 - recent eye surgery
 - puncture of uncompressible vessel
 - uncontrolled HTN (>180/110)
 - IC tumor
- Relative minor
 - hepatic failure with coagulopathy
 - bacterial endocarditis
 - pregnancy
 - diabetic hemorrhagic retinopathy

Best case scenario – lyse clot, uncover stenosis, repair

if central vein - PTA +/- stent,

if at distal anastomosis – revise/proximalize outflow

if axillary – would prefer not to stent – i.e. open repair

13. Loop graft in forearm. High venous pressures on dialysis.

Investigations?

Management?

Review indication for surgery, previous revisions, central lines, alternate sites

Needs fistulogram, then assessment of inflow, graft, outflow, central veins.

Normally flow should be above 600 ml/min

Drop of 25% or below 400 ml/min should prompt investigation

He may need revision of the graft, distal anastomosis, or PTA of central veins +/- venous bypass
Alternative –abandon current site and find different dialysis access.

14. Infected groin AVF graft for dialysis.

How would you manage?

What if this is the only available vascular access – all other exhausted?

Find out if graft is locally infected, if anastomosis is involved.

If only local infection and NO other alternative sites– consider interposition graft through non-involved field or else put a neck dialysis line.

If no veins in neck, forced to try weird and wonderful, e.g. tunneled catheter to IVC, HeRo catheter

15. 70 yof, had her multiple failed AVFs, autologous, no vein on arms. Options?

prosthetic to deep veins (do Dupplex first)

may use GSV if sure no need for lower extremity revascularisation in the imminent future.

Options for central vein occlusion?

go to lower extremity,

GSV vein (does NOT dilate much even if transposed to arm)

Superficial femoral vein transposition

Recanalize SVC

reconstruction (jug turn down, bypass)

IVC cannulation

percutaneous tunneled catheter

HeRO device <http://www.veithsymposium.org/pdf/vei/2090.pdf>

Weird and Wonderful:

Anastomose venous end of catheter to Ax-fem-vein ptfe bypass as venous outflow

Axillary-axillary artery loop

- Bungler, CM JVS 2005, 42(2)-290-295
- Consider peritoneal dialysis

UPPER LIMB:

16. General approach to Upper limb complaints –

Review presenting symptoms –

ischemic, venous, neuro, raynaud

Review

Degree of disability

Treatment taken

- location, laterality

age and smoking,
occupation, vibrational trauma/sports
arrhythmias
hypercoagulable state.
RF for Asc
manifestations of CTD
hx of rads

Specific History:

Epi data:
Age, gender, occupation, provocative maneuvers, hand dominance

Symptoms:
numbness? pain? (**neurogenic**)
ulcers?hand fatigue/claudication?nail splinter hemorrhages (**arterial**)
swelling/catheters/recent strenuous activity? (**venous**)
vasomotor symptoms (**Raynaudes**)

bilaterality
duration,
what tried for relief, course of sx over time,
disability - at work and life style limiting

RF Asc –
HTN, Lipids, DM, smoke, hyperhomocysteinemia

prev hx of:
AF/warfarin/
DVT/Hypercoagulable state
Central lines
CTD/arthritis
Trauma: this may lead to complex regional pain
Neck
Rotator cuff
Hand
Vibration
Compression syndromes
Ulnar
Carpal
Neck DDD

meds: OCP if female

fam Hx: hypercoag state

ROS:

CTD screen –

arthralgia, myalgia, rash, swelling,

xero, digital sclerosis, calcifications, telangectasias, difficulty swallowing (CREST)

systemic –

fever/chills, sleep/energy, appetite/wght loss, night sweats

functional status, degree of disability.

Smoking, sports?

Meds

IV/po - beta blockers, cocaine, CCB – make it beter/worse?

On examination:

BP both arms, pulse quality, distribution, bruits

p2 for pulm htn, chest, axilla, supraclavicular pulse or bruit, abdo for aneurysm

the rest of exam - i.e. other extremity, HS, abdo etc.

Extremities:

inspect - ulcers, atherosclerosis, wasting,

palpate

pulses, equality, Allen, muscle tone/bulk, sensation,

Check for neck pain, Rotator cuff tears/weakness, bicipital tendonitis

splinter hemorrhages

stress test: Adson, EAST, Tinnel, Phalen test

Specific provocative tests –

Adson - radial a. pulse disappears when head turned away & breath in.

EAST – hands up and clench fists...

external rotation, abduction

can't sustain fist clinching for more then 30 sec

auscultate – bruits

neuro exam

CXR:

cervical rib/clavicle abnormality

Lab:

Routine lab, ANA (pattern), ANCA, scl-70, anticentromere AB, RF, ESR

Patterns of ANA:

- SLE – homogenous ANA (systemic=homogenous)
- Scleroderma – speckled ANA (spotty=speckled)

- CREST – anticentromere AB (at the waist, on the crest)

In general, upper limb ischemia is due to: spasm, obstruction or embolism

spasm - ergotamine, raynaudes disease

obstruction:

large vessel –

Asc, TOS, arteritis (Tak, GSA), rad, FMD, DISSECTION,

small –

CTD (Scl, RA, SLE, Sjo),

metabolic (DM, CRF),

myelo (thrombocytopenia, PCV, Cold cryglob, hypercoag, leukemia),

trauma

vibration, cold injury, AVF,

sports

digital a. in baseball catchers

other (Burger, cytotoxic drugs - chemo)

Emboli:

aneu - ventricular, inno, subcl, axil, brach, ulnar

post circumflex artery in baseball/volleyball players

ulnar aneu in carpenters

plaque - arch, inno, subclavi

heart - AF, post MI vent

17. Young female secretary comes in with pain in R arm. Normal pulses.

No obvious neuro deficits. Approach

TOS:

Neuro – 95%

Vein – 4%

Artery – 1%

General Overview:

- Review occupation, neurological, arterial, venous, Raynaud symptoms.
- Assess location, laterality, degree of disability.
- Review pmx of compressive syndrome, neck/shoulder trauma, vibrational/occupational injury, CTD, hypercoag state, AF.

Hx and exam as in previous question:

work up for Neurogenic TOS:

- no test alone is indicative or fully diagnostic
- go by presentation hx and physical
- CXR to check for 1st rib
- Duplex to assess vein and artery
- CTA if suspect aneurysm
- MRI – but may not show much...
- Rutherford recommends test injection of lidocain in ASM
 - If better, then may benefit from surgery discussion

TOS notes:

Neuro – 95%

Vein – 4%

Artery – 1%

There is no good objective test for neurogenic TOS so one can't say it until all else is excluded...
If pt has clinical evidence for neuro TOS and no other abnormality –
strongly encourage physio to avoid surgical intervention.

If that fails, then offer provocative testing – lidocain injection of Anterior Scalene muscle - then DISCUSS (i.e. don't offer right off the bat) surgery if there is a response
Providing pt understands that:

TOD is a diagnostic intervention

- Procedure may not relieve her symptoms –
- Mid term: 80% good to fair response, 5% no change, 15% worse...
- Note that the examiner may freak out if they don't do provocative testing in their institution, so be prepared to defend yourself if you care to walk that road

Note:

- MRI/CT – DON'T provide specific findings or point to diagnosis, high false negative
- EMG/NCS should be normal.
- If suspect arterial/venous TOS – may do venogram and DSA as well.
- If arterial intima is injured, will have implications
- CTA probably best –
- will image both sides
- will give info re: aneurysm size if present
- refer to neurologist to rule out other neurological causes..

so for neurological symptoms, rely primarily on clinical suspicion.

Fortunately, arterial and venous disease is a bit more straightforward:

If pt has TOS and ectasia of her artery is noted but no obvious intimal damage:
this is the first evidence that there may be early compression and injury to the subclavian in TO...

options:

- rib resection/scalenectomy
- add brachial plexus neurolysis to the procedure.
- surveillance with doppler understanding there may be a risk of athero-embolism/acute limb ischemia.

Emphasize that pt's original neurogenic TOS symptoms likely do not relate to her subclavian ectasia and may or may not respond to the intervention.

Continuing Scenario: pt has angio – intimal defect in subclavian artery but she says she is fine and does not want surgery.

- document your discussion and ask for return appointment and duplex in 6/12

She will re-present with L acute limb ischemia - numbness and weakness.

take hx and exam - new activities, what happened, pulses.

She says no ppt'ing event, has pulses in axillary but nil else.

I'll take her to OR for brachial embolectomy and angio

You do preop angio - shows –

- distal brachial a. occlusion.
- subclavian a. intimal defect.

do brachial embolectomy and AC pt.

CT to outline aneurysm (and check other side) and size it up.

3 months of anticoagulation to let the intima heal then elective TOS decompression.

Conduct of TOD:

Advantages of Supraclavicular approach:

- Wider exposure of all anatomic structures
- Complete resection of Anterior SM and Middle SM
- Can resect 1st and accessory ribs
- All forms of vascular reconstruction possible

Advantages of transaxillary:

- Limited dissection, better cosmesis
- Allows partial ASM resection and anomalous bands

Problems:

- Incomplete neurolysis and scalenectomy
- Limited vasc reconstruction possible
- Greater chance of retraction injury to brachial plexus

Supraclavicular approach:

- Complete disclosure and comprehensive consent
- head turned away, arm **free draped** across abdomen
- incision 2 finger breadth above clavicle starting from head of SCM
- skin, platysma, come upon scalene pad
- reflect scalene pad laterally,
- dissect anterior Scalene muscle, ID/protect phrenic n. – travels lat to medial
- Divide ASM with scissors under direct vision, dissect proximally, excise
- Do neurolysis –C5-T1, may have to divide scalene medius
- Test compression of a/v/n between 1st rib and clavicle with moving the arm around
- Free pleura under the rib
- Use rib cutter and Kerrison's bone rongeur.
- Assess artery with angio or Doppler:
- If damaged – do GSV interposition graft.
- May tunnel the vein in 6 mm PTFE graft for external support.
- Leave drain in behind platysma
- Close platysma
- CXR in recovery to check for pneumothorax

- **Description of trans-axillary resection:**

- GA, supine, back elevated 30 degrees
- Fiberoptic head light is a must
- Arm is **free draped**, is held by reliable, flexible, sturdy assistant
- Transverse incision at lower axillary hairline: from Lat Dorsi to Pec Major,
- Skin, sc tissues, down to the chest wall. Superficial veins may need to be tied
- Preserve Long thoracic (exits btw med and post SM, crosses 1st rib to Serratus anterior), TD, and 2nd ICB nerves
- Watch out for excessive retraction on brachial plexus,
- make assistant rest if tired (q 10-15 min)
- this will reduce chance of brachial artery injury with retraction by zealous helper
- With Deaver retractor lift axillary contents away from the thoracic cage superiorly,
- don't compress structures above 1st rib
- ID 1st rib in upper corner of incision, artery, ASM, vein

- Encircle ASM with GB dissector, transect, divide it higher trying to remove a portion of it
- Separate a and v from rib, stay on the rib and go posteriorly partially dividing MSM
- danger point – can injury Long thoracic n.
- Divide soft tissues from inferior and post surface of 1st rib (first muscles, then plura)
- Cut the rib
- Do neurolysis
- Drain, 2 layer closure.

Complications of 1st rib resection:

- Wound hematoma/infection
- Injury to
 - intercostobrachial n.
 - brachial plexus
 - long thoracic n.
 - thoracodorsal n.
 - phrenic n.
 - sympathetic chain
 - vein
 - artery
- pneumothorax
- lymph leak
- persistent/recurrent TOS

18. Axillary vein thrombosis in young male. Management:

- Primary – effort – 25%
- Secondary –
 - Central lines 40%,
 - infection, prev DVT, UE AVF, hypercoag state, trauma – 35%
- pathophysiology:
 - *venous HTN, related to obstruction, rather than reflux*
- *Work up:*
 - Duration of symptoms, required future level of activity, TOS symptoms –
 - Even though suspect venous, always work up for both neuro and arterial TOS as a cause....
 - occupation, provocative maneuvers, hand dominance
 - numbness? weakness? (neurogenic)

- ulcers?hand fatigue/claudeication?nail splinter hemorrhages (arterial swelling? (venous)
 - vasomotor symptoms (Raynodes)
 - bilaterality
 - duration,
 - what tried for relief, course of sxs over time,
 - disabilty - at work and life style limiting
 - prev hx of: carpal/ulnar tunnel, neck trauma, hand trauma, vibrational injury, DDD neck, CTD/rheumatoid arthritis, rotator cuff tears, hypercoag state/DVT, fibromyalgia.
- meds: OCP if female
 - fam Hx: hypercoag state
 - ROS: functional status, degree of disability.
- o/e:
- blood pressure both arms, pulse quality
 - pulse distribution/bruits
 - provocatvie –
 - Adson - radial pulse disappears when head turned the other way, breath in.
 - EAST - exteernal rotation, abduction - can't sustain fist clinching for more then 30 sec
 - wasting, weakness, sensation, reflexes, Tinnel, Phalen test.
 - Check for Rotator cuff tears/weakness, bicipital tendonitis
 - splinter hemorrhages/ulcers/Allen test.
 - the rest of exam - i.e. other extremity, HS, abdo etc.
- investigations:
 - CXR - accessory 1st rib
 - Duplex – to assess flow in artery and vein, intimal damage
 - Hypercoag work up
 - FVL, atIII, pn 20210A pm, pn c&s, lac & acl, fibrinogen, PAI-1, homocysteine, CBC
- Duplex: shows normal artery, thrombosed vein.

Plan:

Observe/elevate/AC vs intervene

Treatment options for primary axillary vein thrombosis:

1. AC, and wait for the clot to go away, vein to recanalize

2. Catheter Directed Thrombolysis, to actively open up vein
3. Thoracic outlet decompression if external compression demonstrated,
4. Open Angioplasty vs stent for intrinsic residual stenosis in the vein,
5. surgical bypass for failed thrombolysis AND disabling symptoms.

Confusion and variation begin when you factor in timing and order of these interventions...
Here is the above list with timing considerations:

A. CONSERVATIVE approach:

- Arm Elevation/Rest alone
 - not practical for most active patients
 - for high risk only with minimal function and AC Contraindications
- **Anticoagulation/arm elevation/rest alone**
 - **Preferred approach for majority of conservative hematologists**
 - **Poor functional results according to Rutherford...**

Please note, that AC alone makes no difference on degree of future disability – i.e. it does not improve function much.

PE incidence – 7%

INTERVENTIONAL approach:

open up vein with CDT (most commonly) vs open surgical (not common as a stand alone – unless combine with immediate TOD and open venoplasty)

Questions arise as to WHEN to do TOD if such is diagnosed:

open up vein with CDT and/OR anticoagulate for 3 months, then venogram

- **if external compression alone, then TOD. Most common scenario.**
- If internal defect alone, open venoplasty vs balloon/stent

if normal venogram – 3 months of AC/AE/R.

Least common scenario.

Then decide on stopping AC vs continuing...

Adjuncts for vein defects:

- for short stenotic segment
 - a. open venoplasty
 - b. endovascular plasty +/- stenting
- for long stenotic segment

- a. trial of AC/AE/R. If fail, then consider venous bypass or IJ turndown

TOD:

On exam, the classic answer would be to lyse (if no contraindications), keep AC for 3 months, then bring for delayed TOD if indicated by venogram.

MAKE sure you let the pt choose and review complications of thrombolysis (IC hemorrhage) as well as contraindications to thrombolysis.

19. Young man with ischemic R 4th finger.

Approach and DD

Smoking only – no other findings/riks/hx

N pulses at wrist

DD, preferred Ds?

- Embolism vs thrombosis
- Spasm:
- Drug injection
- Raynaudes syndrome
- unilateral, ulcer
- in Raynaudes disease, usually bilateral, no ulcers....

Embolus from:

- Aneurysm vs artery vs heart
- Thrombosis
- Aneurysm/ TOS
- CTD
- vasculitis
- Vib trauma
- Buerger

Investigations:

- duplex (N), b/l digital pressures – none in 3rd, reduced in other, N on the R.
- CTD screen normal
- ESR, CRP, ANA, Scl 70, anticentromere

CXR normal

MR normal – no aneurysm, no bone/soft tissue abnormality

Angio – no plaque, intact palmar arch, 3rd digital artery occlusion.

Echo – normal

Addson & EAST can be positive in normal, so go by CLINICAL hx and presentation primarily..

In this pt, with no evidence of source of embolus, ASC changes, neg CTD screen - in view of smoking Buerger disease should be considered strongly.

PLAN: Smoking cessation, CCB, iloprost iv.

Worsening pain in 2-3 months. Management?

- Reimage, restudy
- If found subclavian a. defect/aneu – need to do TOD
- TOS – ethiology, OR, approach
- Any role for Cervical sympathectomy?
- Indications & technique

Upper extremity sympathectomy:

- Indications:
 - Hyperhydrosis
 - CRPS
 - Raynaud's disease (high recurrence)

How:

1. Open (transaxillary - painful, paravertebral – extensive dissection, supraclavicular – high incidence of Horner's)
2. Thoracoscopic:
 - Collapse lung
 - Visualize 1st 4 rib/vertebra
 - ID subclavian a. – superior extent of dissection
 - Sympathetic chain – dorsal, phrenic/vagus nerve – ventral
 - Remove all sympathetic ganglia below T1 – i.e. t2 and t3.
 - Leave stellate ganglion intact – otherwise horner's:
 - Upper ptosis (Muller's muscle denervation)
 - Lower upside ptosis
 - Myosis
 - +/- enhydrosis and loss of ciliospinal reflex (neck pain – skin prick - causes ipsilateral pupil dilation)

How does sympathectomy work?

- Increase in blood flow
 - Drop in resting vasomotor tone
 - Most of increase is non-nutritive, via AVF
 - Diminishes after 5 days (5th day phenomenon), resting vasomotor tone returns to normal in 6/12
- Collateral flow increase:
 - Average 11% increase in flow in animal models

- Alteration in pain perception
 - Effective for rest pain
 - Central and peripheral signal conduction attenuation

Aside: reactive hyperemia and prediction of response to sympathectomy.

- Reactive hyperemia:
 - Substitute for exercise
 - 3-7 min suprasystolic pressure on thigh
 - Monitor ankle pressure at 15 sec then 30 sec interval
 - Normal response – Pressure initially drops to 80% but comes back to 90% within 30-60 sec.
 - Toe pressures
 - Assessment of functional severity
 - Shows degree of maximal dilation of peripheral bed
 - reappear almost immediately, but with 2 fold increase in amplitude.
 - Abnormal – toe pressure does not come back for > 120 sec
- Surgical sympathectomy and hyperemia response:
 - If posthyperemia response – twice prehyperemia – may benefit from sympathectomy
 - Measures an ability to dilate in response to a release in vascular tone
 - **Not a test of integrity of sympathetic system**
 - To check function:
 - PVR will decrease with deep breath if sympathetic is intact
- Overall - between healing superficial ulcer and relief of rest pain, sympathectomy is more likely to help with RP: need less increase in blood flow & due to pain impulse attenuation

Aside: review of causes of Upper extremity ischemia

spasm - ergotamine, raynaudes disease

obstruction:

large vessel –

Asc, TOS, arteritis (Tak, GSA), rad, FMD, DISSECTION,

small –

CTD (Scl, RA, SLE, Sjo),

metab (DM, CRF),

myelo (thrombocytopenia, PCV, Cold cryglob, hypercoag, leukemia),

trauma

vibration, cold injury, AVF,

sports

digital a in baseball catchers

other (Burger, cytotoxic drugs - chemo)

Emboli:

aneu - ventricular, inno, subcl, axil, brach, ulnar

post circumflex artery in baseball/volleyball players

plaque - arch, inno,subclavi

heart - AF, post MI vent

20. 65 yom with acute onset R upper limb pain, weakness and numbness.

Nil on hx. PE - bounding brachial, nil distally, painful weak numb hand.

I asked for heparin right away and plan to go to OR as it is 2b ischemia (defined).

OR Plan:

CONSENT, antibiotics, positioning

brachial embolectomy and then on-table angio to look at the proximal embolism sources and effect of embolectomy.

How to do on-table angio?

awkward, protection for everybody, C-arm, angio table, power injector to see arch, incline tube, run-off pictures.

On the way to OR - radial signal appeared, hand pinked up.

I said will go to angiosuite as it is Rutherford 2a ischemia now (defined – no motor, slight neuro deficit).

Angio - normal arch, subclavian, occluded ulnar.

I said he will need to be watched closely, kept anticoagulated, and a search for embolic source be undertaken. Meanwhile may consider CDT if Rutherford 2a ischemia.

ECHO, hypercoagulable state, CT angio arch - if not happy with regular angio.
Echo - hypokinetic segment. Nil else.
His hand is improved, he is functional now.

Plan:

life long anticoagulation as he has an unknown source of emboli.
May be from the heart but that is not correctable. Hence, warfarin.
Asked how to start – overlap with heparin, doses, etc.

In reality, this guy died in a week with acute ischemic stroke... same source, while anticoagulated. They tried mercy retriever, caused SAH, no luck...

21.Lady with confirmed L subclavian steal. symptomatic. nil on hx.

management:

if decided to intervene, confirm with duplex, then angio.
Study carotids with duplex, id which vertebral is dominant.
need dominant vert to be on the steal side for sxs..
angio
proximal subclavian occlusion,
2 cm prox to vertebral are open.
Look for evidence of distal embolization
i.e. ulnar occlusion, as this was the case here on angio...

Wants surgery:

endo (no aortic nub - risk of distal and prox (vert) emboli, rupture, long term patency)
open
extranatomic bypass - transposition vs bypass with 6-8 mm ptfе ringed graft.
Transthoracic (ascending to subclavian bypass). Possibly an overkill option here...

SN would use bypass all the time, too finicky to deal with short stump of deep subclavian that need ligation You'll need to go proximal to IMA and vertebral...So he goes for bypass all the time.

Note re: clamping the carotid:

For exam you want to be comfortable with whatever route you decide: so you need to ooze calm confidence... 😊

clamp vs check pressure vs shunt

if carotids are totally normal, then just clamp, ephasizing that
it is not the flow but embolism a risk factor with diseased carotid that causes strokes
that ECA is still open to back perfuse ICA...

If desired, may measure back pressure

Or ask for intracerebral angio to confirm patency of anterior communicating arteriес and cross flow (going overboard here)...

Shunt is a difficult proposition - small hole and deep.
May want to use it if concomitant CEA is planned.

Asked how to do dissection, how to cut ant. scalene (scissors, not cautery) what to look out for (phrenic lateral to medial, TD on R, easy on brachial plexus)
If R sided steal (R innominate stenosis) in conjunction with R CCA/ICA disease that needs endo, may do retrograde innominate stenting during R sided CEA. Alternative (if innominate is gone) L to R xover carotid bypass behind esophagus.

22. Angio - case with innominate, subclavian and SFA/SMA/Brachial stenosis...

Normal arch. Older woman. Suspect vasculitis.

DD of vasculitis –
large vessel vs small. It is likely GCA but no confirmation.
Other differential: Takayasu, NF

plan

treat with steroids through active stage,
then if sx of ischemia (limb, brain, visceral) endo is the 1st choice
recognizing unknown durability of this technique...
If endo fails, then have to revascularize –
ideally extrathoracic
if have to - ascending aortic inflow to the target artery
Lemole-Strong side clamp.

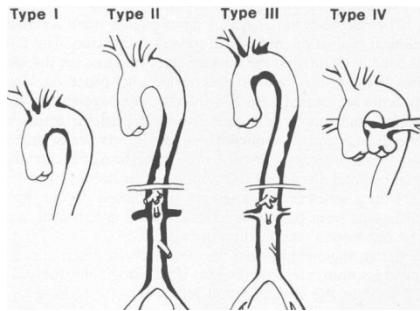
23. Young female with HTN on one arm, low pressure on the other.

Angio – smooth tapered stenosis of aortic branches (innominate) and renal a.

- Differential Dx
- Management options?
- When to consider surgery?
- surgical management of a symptomatic proximal innominate artery lesion

Types of Takayasu Arteritis: modified Ueno classification

- aortic arch only: 40%
- descending thoracic and abdo aorta – middle aortic : 11%
- involves both 1. and 2. : 65%
- pulmonary artery involvement + 1-3: 15%



- Unknown etiology
- Pan-arteritis,
- Patchy involvement
- Transmural involvement
 - Won't be able to develop endarterectomy plane
 - i.e. No endarterectomy or patch angioplasty – bypass...
- Granulomatous lesions, but no caseation or cavitation
- Responds to systemic steroids and cytotoxic drugs
- Surgery for aneurysm, in burnt out stage

Stages:

- Prodromal part
- Inflammatory
- Burned out

Clinical presentations:

- Stroke
 - CHF
 - HTN
 - CRF
 - Aneurysm
- Mortality due to uncontrolled hypertension: stroke, CHF
 - Can't reliably follow stages using labs, need to have serial imaging.
 - Main pathology is stenosis/obstruction:

Long stenosis –

- Sparing ascending aorta (in 95% of cases)
- For carotid stenosis:
 - bypass to the level of the carotid bulb (transthoracic)
- for Renal artery stenosis:

- may consider PTA 1st for renal a. stenosis –up to 90% success (but poor long term results for other locations)
- for Infrarenal aorta stenosis – up to (but not at) the level of bifurcation
 - May consider thoracic aorta -> single iliac bypass – will reperfuse the other extremity via bifurcation...
- Innominate artery/subclavian:
 - Bypass to subclavian/axillary artery as second stage (extrathoracic, off carotid bypass)
 - to be able to diagnose HTN (by arm BP measurement) – most important cause of mortality in Takayasu

Important: make sure disease is in burned out stage before bypassing.

24. Middle aged construction worker, numbness, pain, ulcer in 5th digit.

DDx. Approach. Management.

Recurrent palm trauma

Ulnar a. aneurysm

Work up with angio

Offer repair

AORTA – Aortoiliac insufficiency:

25. In AIOD setting, always ask re:

Buttock pain/impotence

Blue/painful toes

IC/RP/ulcer

Claud distance

Management of RF

If pt has AAA in addition to AIOD, then add...

AAA stuff...

Epi (race, gender, age)

Symptoms: abdo, back pain, blue toe/ass

High probability RF for detecting – smoking, lipids, CAD, FH

Low probability RF for detecting – DM, DVT, N abdo imaging

RF for repair: MI, CVA, CRF, COPD, HTN,

level of activity, longevity assessment

26. Elderly male, severe b/l claudication, no other medical hx.

ABI 0.3 bilaterally. Approach and management:

Confirm:

Claudication distance

Buttock pain/Impotence

Foot ulcer/RP

RF and their manifestation (TIA/CVA/MI/vasc surgery) & management

Trial of walking

Functional level (walk the stairs, independent shower, sex, makes own bed) – 4 METs

Life expectancy assessment

Exam:

VS, HR, HS, bruits, AAA, pulses, stigmata, scars

If no acute ischemia, needs more work up:

Labs:

ECG, routine labs, lipid profile, carotid duplex if bruit, anesthesia work up, cardiology/testing if poor METs/clinical indication.

Suspect AIOD:

obtain CTA (chest to feet)

DSA is second option – can't see aortic thrombus

if ordering DSA, prepare to discuss alternative puncture sites

brachial, axillary, translumbar, femoral

CTA shows: renal ok, aorta occluded below renals down to the iliacs.

Options:

Axillo-bi-fem for poor risk,

aorto-bi-fem for good risk.

Details of ABF:

Consent, complications discussed

- Hemorrhage
- Death
- Ischemia
 - cerebral
 - spinal
 - Myocardial
 - Colon
 - Renal

- Limb
- Ureter injury
- Infection:
 - Pneumonia
 - graft,
 - wound
- Wound related
 - Original extremity wound non-healing
 - Operative wound non-healing
 - Nerve injury
 - Seroma/lymphocele
- Impotence/retrograde edjaculation
- Recurrence:
 - Graft dilatation
 - Pseudoaneurysm

Supine, GA

Monitoring, lines, foley, abx

Dissect groins first, pack with antibiotic soaked gauze

Laparotomy, duodenal mobilization

Dissect supra/infra renal, renals, heparin.

Decide on End to End vs End to Side:

See ASIDE below

Top up iv fluids, ask anesthesia to give manitol
heparinize

Prepare to clamp suprarenal (but don't clamp),

Open up infrarenal aorta, flush out thrombus plug,

Control renal arteries with loops

Clamp SR clamp

Move clamp to infrarenal site,

reperfuse kidneys,

Proximal anastomosis

flush

Tunnel behind ureter (stay on calcified iliacs)

Profundoplasty if necessary.

ASIDE:

Indication for End to End vs End to Side for ABF (aortobifemoral):

- End-to-End ABF bypass configuration
 - Better HD configuration (theoretical)
 - Better tissue coverage
 - Indicated for aneurismal aortic/iliac

Canadian Vascular Surgery In-Training Cases, U of Ottawa, Anton Sharapov, MD, 2008

- Easier clamp placement
- End-to-Side ABF bypass configuration is preferred when:
 - When preservation flow is required in the following systems:
 - IMA flow
 - Blood supply to colon&pelvis is preserved
 - accessory renal a. flow and horseshoe kidney
 - significant median sacral and lumbar a. flow
 - spinal cord preservation
 - occluded External Iliac Artery
 - internal iliac system flow can't be preserved with End to End configuration – i.e. can't reperfuse these in a retrograde fashion
 - Fringe benefit of End to Side:
 - if bypass occludes, pt is back to original state,
 - with residual iliac system functioning may at least do AKA

Indication for **Axillo-bi-femoral Graft:**

- AIOD in pts with CRITICAL limb ischemia not suitable for ABF:
 - Poor surgical/medical risk
 - Hostile abdomen
 - Note: HD results of ax-fem **MAY NOT significantly improve claudication distance**, hence reserve procedure for SEVERE claudication and CLI only...
- To revascularize lower extremities following removal of an infected graft
 - Aortic graft
 - One limb of ABF
 - Fem-fem graft
- Treating LE critical limb ischemia following aortic type B dissection

Complications of Axillo-bi-fem:

- Upper limb ischememia
 - Steal
 - Anastomotic pseudoaneurysm
 - Arterial distortion causing kinking/thrombosis
 - Thrombosis with UE embolization
- Brachial plexus injury

Note, if anastomosis is made to 1st portion of axil artery, anastomotic disruption with sudden arm abduction is less likely.

27.65 yom, farmer, c/o of blue toes. Take it from there.

Thorough vascular history:

Toes:

- how long? both legs? painful? coping at home/rest pain? all toes?
- impotence/butt pain/IC/rest pain/tissue loss/ Claudication distance?
- RF: high chol, htn, dm, smoking

- manifestation of RF: cva, mi, pvd
- management of RF:
 - quit smoking (quitting program, champix)
 - statin, antiplatelet, acei, tried exercise and walking?

- ROS: fitness, 4 mets of activity, CP/SOB, constitutional sxs
- pmh: other med problems, surgeries/bypasses, aneurysms, arrhythmias, hypercoag states
- other meds and allergies
- fam hx: premature CAD/CVA, aneurysms

he is not on lipid/aspirin, still smokes, active, DM, toes hurt for 2 weeks, blue, bilateral. coping, no IC/rest pain/ulcers. farmer

o/e: he has blue toes, all pulses ok, no AAA.

- Likely has arterio-arterial atheroembolic disease.
 - most likely source
 - if bilateral - infrarenal aorta, then thoracic aorta.
 - If unilateral – fem, pop, then aorta.
 - R/o heart as embolic source!

Plan:

- optimize RF
 - quit smoking, start ASA or ADD plavix, start lipitor, arrange BW and studies.
- BW:
 - hypercoagulable screen,
 - BUN/Cr/lytes looking for renal impairment,
 - CBC looking for **eosinophils**,
 - u/a - looking for protein and chol crystals
 - **if present, source likely suprarenal,**
 - LFTs for fam doc for statin baseline, fasting Lipid profile.

GOAL: want to stabilize plaque - antiplatelet and statin, htn control.

- investigations:
 - ECG +/- ECHO,
 - CT chest - legs - CTA...
 - not angio (want to see aortic wall and lumen plus outflow...).

If asked for Duplex – it will show some abdominal aortic irregularity, iliac irregularity, normal all else to legs, abi 0.9, i.e. NOT HELPFUL. Go for CTA from the start...

- So i said i'll see him in the clinic again in 3 months. On my practice oral, I did not order CTA right away.

Pt calls back and says can't sleep - now has rubor on the dorsum of foot. He is taking plavix and aspirin...

- re-examined - rubor and palor distal foot but he has all distal pulses.
- I said i'll admit and start him on heparin and order CT scan
- After i mentioned heparin....

pt now has ischemic feet b/l and his distal pulses are gone. Still has femoral pulses. He has motor and sensory impairment.

- I said, hmmm -? HIT unlikely, but i will stop heparin, and given this is 2B acute limb ischemia will take him to OR for on table angio and b/l pop artery exploration and embolectomy. Will send blood for ELISA for HIT. I fished out clot and crystals crap from his tibials - he is reperfused now. Still has blue toes.

As it turns out, heparin is contraindicated in atherembolic disease, so is anticoagulation - can make it worse. Rutherford is not entirely clear on that one, but two different established vascular surgeons confirmed this to be the case (in Ottawa and Calgary). Heparin destabilizes the plaque, apparently...

Next?

- well, finally i reviewed CT - thoracic down to iliac aortic disease with layer of clot throughout... no free floating clot.

what next?

- I said i'll do TEE - nothing new, no clot in heart, diseased aorta.

PLAN:

- Pt failed his medical therapy - asa and statin. He needs surgery.
- In an active guy - ABF is a good start - most of A->A atheroemboli from infrarenal aorta
 - plus tie off EIA - do end to side - to perfuse iliacs and ima here
 - If he continues to throw athero-embolism –
 - line thoracic aorta with stent.
 - Risk of spinal ischemia
 - in Rutherford: for thoracic/arch ulcer thick plaque > 4mm will put pt on warfarin - some studies say it is protective.

Variation in the case:

- Ulcer in R CIA close to origin of iliac artery
- No stenosis
 - So technically TASC II does not apply....
- Would you cover ulcer ?
 - use a covered stent
 - Atrium, Fluency or Viabahn
 - don't cover orifice of IIA
 - or consider embolization of IIA
 - Otherwise, use non-covered stent to stabilize plaque
 - May go over the IIA origin
 - Express (rigid for CIA), EVE3/Smart/Epique (flexible)
 - Consider open if endo fails: endarterectomy/patching
 - RP open CIA repair

28. 65 yom, farmer, disabling claudication, half a block. Smoker, all other RF normal.

complete hx.

- establish thorough vasc hx.
- establish type of claudication: economic and disabling life style.
- establish proposed improvement with further RF management - quitting smoking, cilostazole, walking.

Exam: all normal except, no fem and distal pulses, ABI 0.5. No tissue loss.

Plan:

- i said in view of likely etiology, consider aorto iliac disease, economic claudication,
- i would advise that he undergo further investigation
 - while modifying his RF (quit smoking, statin, ASA).

- Why further investigation?
 - modification of his RF at best will double his walking distance - and 1 block won't be enough for him.
 - He may have an easy low morbidity task A lesion that can be treated endovascularly...
- What next? duplex.
 - shows occluded aorta infrarenal to distal CIA bilaterally. Next?
- He has task D lesion that can be addressed with surgery.
 - So if he is still eager to have it fixed (and he is) then
 - Make sure he understand this is life-style, not limb saving surgery
 - review his ROS, angina, met 4 level of activity,
 - send to cardiology/anesthesia for clarification of status/persantine.
 - Order CT.
 - Review his aorta above renals (normal), SMA/cealic (normal), prev colonic surgery (no), IMA (occluded) and int iliacs - open.
 - Review outflow - normal.

Conduct of surgery.

- How?
 - Consent and COMPLICATION discussion
 - abx. bowel prep preop. dissect out everything first, tunnel under ureters,
 - prepare to clamp above renals and below,
 - incise aorta distally below renals,
 - if decided EtE – transect, if EtS – then longitudinal
 - protect renals, blow out the plug, apply suprarenal clamp,
 - endarterectomize if necessary and reposition the clamp infrarenally,
 - do end to end close to renals and end to side on CFA if outflow is ok (it's ok).

advantages of EE?

- better HD config
 - no proven patency advantage over ES,
 - better tissue coverage
 - the only option for aneurismal disease
 - easier clamp application (no satinsky sideclamp)
- Can't do end to end if
 - IMA is huge and feeding SMA (may reimplant),
 - if internal iliacs are open and external iliacs are occluded,
 - if accessory renal a. is present from lower aorta.
- In this case - End to side is better... keep prograde flow...

29. Limb of ABF is occluded on angio, acute limb ischemia.

Worsening claudication past year, RF no controlled, continues to smoke. Good runoff.
Approach.

History:

- Epidemiology (age, gender, race)
- Limb: 4 Ps of history – pain, paresthesia, cold, paralysis
- Aortoiliac insufficiency SXS:
 - Impotence/butt pain/ Claudication distance/RP/ulcer
- Reason for original ABF (claudication vs aneurysm vs CLI)
- DURATION of symptoms
- WHEN the repair was done:
 - Recent repair (technical error) vs
 - old (disease progression, embolus, thrombosis)
- Level of activity and claudication

- RF:
 - Arrhythmia, recent MI, valve replacement, AC therapy
 - Hypercoag state
 - Low flow (MI, hypotension, sepsis)
 - Atherosclerosis RF and their management

- Prev vasc surgeries
- MI/CVA/DM/CRF/COPD
- ROS for METS/activity

Exam:

- VS, arrhythmia, general appearance
- HS, bruits, abdo masses/pulsation, femoral and distal pulses
- 2 Ps of exam: pale and pulseless
- Stigmata of arterial and venous disease
 - cap refill, hair, ulcers, wasting, edema, lipodermatosclerosis, skin atrophy
- Contralateral limb check healthy vs diseased

Plan:

- foley, fluids, start heparin,

- studies/labs:
 - ECG,

 - Doppler pop fossa in ER,

- CBC (Hb , Hct, WBC), Cr (for angio), lytes (metabolic problems), CK & urine myoglobin (myositis),
- CXR, cross match, PT/PTT
- Classify ALI
- Decide on angio suite vs OR/angio
 - If onset is acute (<3 weeks) AND class 1 –
 - Angio first, include thoracic aorta -> distal run off.
 - may attempt CDT
 - urokinase 250,000 u, then 2000-4000 u/min for 2 hours, then 1000-2000 u/min OR
 - tPA – 0.05-0.1 u/kg/h for up to 48 h
 - If failed CDT after 48 h or develops class 2B – to OR/intraop angio.
 - After thorough discussion, get consent for
 - thrombectomy, possible bypass, possible fem-fem/ax-fem
 - discuss need for 4 compartment fasciotomy
 - GA, Supine, warm room, top up heparin, abx, monitoring line,
 - Prep neck-> ankles B/L, on fluoro table, C-arm available
 - Groin dissection, long arteriotomy.
 - Check inflow, restore with embolectomy –
 - Fogarty: 4& 5 proximally, 2 & 3 distally
 - Otherwise consider fem-fem or ax-fem or re-do ilio fem through RP incision
 - Check anastomosis

- Check outflow – SFA and profunda, angio if necessary
- Profundoplasty if necessary
- Completion angio
- Consider fasciotomy if > 6 h ischemia
- Consider keeping anticoagulated

Variation:

- mass is seen in the groin post ABF – pseudoaneurysm. Not infected. How to fix?
 - R/o infection
 - Image entire graft to assess all anastomosis
 - In situ repair if >2.5 cm or symptomatic
 - See pseudoaneurysm in Complications section in Minimum

ASIDE:

General Etiology of post op Acute Leg ischemia post AAA repair:

- Thrombosis:
 - limb of Dacron graft
 - diseased iliac, cfa, sfa, pop
 - pop a. aneurysm
 - hypercoagulable state
- emboli:
 - of aneurismal/cardiac thrombus
 - of dislodged plaque (atheroemboli)

Causes of arterial thrombosis EXPANDED:

- Low flow:
 - CHF
 - cardiogenic shock
 - hypotension
- vascular graft problems
 - thrombogenic (Dacron)
 - disease progression (vein)
 - intimal hyperplasia (vein)
 - mechanical kink (both)
- outflow obstruction:
 - graft – intimal flap

- arterial
 - progression of Atherosclerosis
 - in iliac, CFA, SFA, pop)
 - arterial dissection
 - thrombosis of pop aneurysm
 - venous – compartment, phlegmasia
- hypercoagulable state
- trauma: spasm vs compression vs disruption
 - penetrating
 - blunt
 - drug abuse
 - endo procedure induced

Causes of arterial embolism EXPANDED

heart:

atherosclerotic heart disease:

MI,

Arrhythmias

Atrial myxoma

Valvular heart disease:

RF,

Degenerative,

Congenital,

Bacterial,

Prosthetic

artery to artery:

aneurysm,

atherosclerotic plaque

bilateral: infrarenal > suprarenal aorta

unilateral: fem>pop>iliac>aorta

Vein to Artery: via PFO, Paradoxical

Idiopathic

To prevent:

1. Heparinize pt prior to clamping
2. Back bleed iliacs prior to proximal clamp removal
3. Flush graft prior to distal clamp removal
4. Liberal use of Fogarty

Indications for fasciotomy?

More than 6 h ischemia?

Signs of myositis or elevated compartment pressure

Inability to monitor limbs (i.e. intubated/sedated?)

Concomitant arterial/venous injury (controversial)

30. Angio on a claudicant done - R CIA 3 cm occlusion. What next?

- Tasc B lesion: occluded CIA.
- What's tascII?
 - Consensus statement from experts in North America and Europe
 - Re: evidence based tx of vascular disease
 - Lesion classification:
 - A - endo is better than open,
 - B - endo and open are equivalent, but endo preferred,
 - C - the other way around,
 - D - only open (abf or axbf).
 - Iliac lesions:
 - A
 - CIA stenosis: uni or bilateral
 - EIA stenosis <3 cm: uni or bilateral
 - B
 - < 3 cm aortic stenosis
 - Unilateral CIA occlusion
 - Unilateral EIA occlusion
 - Not involving IIA or CFA
 - C
 - b/l CIA occlusion
 - b/l EIA stenosis not extending into CFA 3-10 cm
 - uni EIA stenosis extending into CFA
 - D
 - Infrarenal occlusion
 - Aortic Aneurysm
 - Uni stenosis of both CIA/EIA
 - b/l occlusion of EIA

What next?

- Recanalize.
- SIA vs transluminal?

- prefer transluminal (SIA in iliacs - risks perforation)
- how? described
 - need to do CL 4 fr sheath to see the distal aorta as target
- how to estimate size?
 - internal calibration, pig tail, coin, external marker, small 5 mm balloon.
- PTA vs stent?
 - PTA plus selective stent.
 - dutch study says selective stenting if failure of pta.
 - metanalysis - suggest stent is good for all CIA.
- any concerns with stents?
 - kissing if close to prox iliacs
 - cant' get over bifurcation in the future
 - infection
 - perforation
 - careful with kissing stents – if overinflate in small aorta, may rupture aortoiliac junction, i.e. need to size both Iliacs and aorta...
 - may have 1 cm iliacs b/l and only 1.5 cm aorta – use 8 mm balloons b/l or single 1 cm balloon unilaterally
- **pt has CV collapse after you ballooned your stents in place:**
 - I'll be grateful for thinking ahead and prepping abdo for ANY iliac recanalization procedures
 - notify anesthesia to start fluids and get blood
 - get emergency laparotomy cart and vasc clamps in the room
 - I'll get C-arm back if it is in the room and handy,
 - put 12 Fr sheath in CL groin - wire - coda balloon & occlude distal aorta –
 - back injection ipsi sheath - id perforation
 - cover hole with balloon.
 - Assess if good candidate for covered stent vs open.
 - Evaluate landing zone
 - Presence and SIZE of IMA
 - if no C-arm and no access - asleep and laparotomy

31. Angio - called to IR suite - 50% stenosis R CIA - no obvious calcification

Also has 3.5 cm infrarenal aorta ectasia. radiologist wants to balloon.

- this is task D - aortic aneurysm and iliac disease.
- back off. do CTA - to asses for aneurysm in the R CIA.

- Don't balloon it - may be ballooning aneurysmal disease.

32. Angio - disabling claudicant with 30% lesion in prox CIA on AP.

nil else, outflow is ok. next?

- i'll do oblique views - 50% stenosis. I'll do gradient.
- How? explained.
 - Ideally simultaneous sheath below and catheter above
 - Otherwise pull through catheter
 - Gradient is 7 mm – borderline...
- I'll do provocative test - nitro or reactive hyperemia.

33. Complete aortic occlusion on angio.

Pt has rest pain, no ulcers

i.e. need to fix

Plan?

RF assessment, CTA/runoff, decide on ax vs aorto fem

Operative approach?

EtE vs EtS

Management of renal vein?

May ligate L Renal over aorta if lumbar and adrenal is preserved

Rarely required

How to construct proximal anastomosis?

Control renals -> fluid load/mantol -> Suprarenal clamp->extract aortic thrombus >infrarenal clamp.

Post op – hematuria, then anuria. DD? Management?

Renal atheroemboli – how to avoid, manage?

Notes: Renal failure postop

- Pre, parenchimal, post renal
- Most common is prerenal
 - volume related
 - cardiac output related
- DD parenchimal renal failure
 - Contrast nephropathy
 - ischemia
 - Embolism
 - Cardiac
 - Clot
 - Atrial myxoma

- SBE, ABE
 - Arterio-arterial
 - Aorta
 - Renal a. stenosis or aneurysm
 - Thrombosis:
 - Atherosclerotic occlusion of renal artery
 - Weird and wonderful:
 - Necrotizing vasculitis
 - Thrombotic thrombocytopenic purpura
 - Antiphospholipid antibody
 - Multiple myeloma
- Lab – unhelpful
 - Eosinophilia
 - ESR, CRP up
 - UA – see urine sediment in ATN (dirty brown cast)
- Consider time frame:
 - Contrast nephropathy –
 - renal failure within 72h
 - renal failure usually recovers
 - normal blood pressure
 - Renal failure due to Atheroembolism –
 - rise in creatinine may be delayed by a week
 - refractory hypertension
 - renal failure mostly non-reversible
 - poor outcome:
 - 1 year mortality 64-81%, due to cardiac, CVA, GI ischemia

Treatment: applies to atheroembolic treatment in general

1. Control source of atheroemboli
 - a. Exclude with open surgery vs cover with endo - stent
2. Physiologic Stabilization of plaque:
 - Statins
 - Antiplatelets
 - ACEI
 - Platelet infusions?
 - Iloprost?

Management of Arch/thoracic aorta plaque –

- if >5mm thick:

- 33% annual risk of vascular events vs 7% in control.
- Overall, non-calcified and at least 4 mm plaque are a risk factor for atherembolism
 - It is suggested to start warfarin on these pts (ACCP, 2001)
 - Better than ASA alone
 - Combined with statin
- Surgery –
 - Option for minority only
 - only on highly selected pts, low OR risk, have multiple documented embolic events despite medical therapy
 - involves relining/replacing large portions of diseased aorta
 - high risk of spinal ischemia

AORTA -ANEURYSM:

34. Questions you'd always ask when have an "AAA" situation:

Age, gender, race

Symptoms

Back/flank pain/abdo/groin pain/blue toes

See if you can REPRODUCE these SXS with EXAM

i.e. if you can turn SXS into SIGNS – then AAA is symptomatic

CAD, COPD, high chol, smoking, FH

these are likely to have AAA

DM, DVT, recent abdo imaging

these are unlikely to have AAA

Morbidity RF:

CVA, CRF, CHF, angina, IDDM

to assess morbidity of elective repair

ROS fitness:

METS of activity, ambulatory status, expected longevity

FH

Screening recommendations:

SVS – one time US:

Male 60-85 yoa

Female 60-85 yoa WITH RF (smoking, high chol, CAD)

All pts with FH after 50 yoa

What to do with US results:

<3 cm – stop

Canadian Vascular Surgery In-Training Cases, U of Ottawa, Anton Sharapov, MD, 2008

3-4 cm – annual
4-4.5 cm – q 6 months
>4.5 cm q 3 months

Aside:

The following RF increase odds of detecting AAA

Gender (M)
Age (odds up q 7 years)
High cholesterol
CAD
COPD
Smoking
Fam Hx

These have decreased odds of detecting AAA:

Recent Normal abdo imaging
DVT
DM
Black race
Female gender

RF for rupture:

Independent:
Female gender
HTN
COPD
Smoking
Size
Probable:
FH
Rapid expansion
Lack of thrombus

RF for elective repair:

CRF
CHF
ECG evidence ischemia
CVA
Pulm dysfunction
Older age
Female gender
use Lee criteria...
IDDM
CHF
Angina/CAD
CRF > 180 or >2
Thoraci/abdominal/Aortic surgery

35. Called from ER re: hypotensive pt with pulsatile mass. Take over.

Preliminary note: while aorto caval fistula (ACF) are not common, for exam purposes, EVERY rupture has ACF until proven otherwise. Maintain high index of suspicion and inquire re:

Canadian Vascular Surgery In-Training Cases, U of Ottawa, Anton Sharapov, MD, 2008

CHF/SOB/leg swelling OR concomitant leg ischemia, machinery abdo bruit, RUQ pain, JVP up...

Questions to ask while on the phone:

- Mentating well to maintain airway?
 - Low threshold for intubation
- Sating well and breathing ok?
 - Ask for O2
- Vitals ?- SBP 90, HR 120
 - Ask for permissive hypotension to allow good mentation and absence of angina (MAP 65).
- Ask for 10 units x-match, 2 large bore ivs, foley, notify OR/partner/help and then go and examine:

Exam:

- reassess ABC
- Maintain permissive hypotension
- Abdo: tender mass,
- femoral and distal pulses
- CHF?
- Machinery abdo bruit?
- lower extremity swelling and RUQ tenderness (RHF)

- Ascertain BP is still stable: continue with permissive hypotension and get more Hx:

- demographics (age/gender)
- known aneurysm? prev imaging? prev discussions re repair?
- RF (MI, stroke, DM, RF, PVD)
- prev cardiology assessment/CABG
- prev abdo surgery

How about CT?

- May go to CT if stable (even if permissively hypotensive) AND think EVAR is an option here (high risk patient, obese, COPD, and local expertise available)
- CT to :
 - confirm diagnosis,
 - define anatomy,
 - plan for possible stent,
 - r/o complications (aorto-caval fistula, bowel ischemia, iliac vessel status)

- Signs of ACF on CT and exam?
 - contrast in IVC in arterial phase,

Canadian Vascular Surgery In-Training Cases, U of Ottawa, Anton Sharapov, MD, 2008

- on exam - machinery bruit,
- liver engorgement,
- lower extremity swelling.
- CHF

Would you consider EVAR?

- More comfortable with open.
- Consider if excessive risk for open, if adequate stock of ER stents and help available.

It is probably NOT a good idea to mention that you'll CT first UNLESS you have compelling reasons to consider EVAR preferentially (old, debilitated, hostile abdomen, COPD, etc...). In this case, do EVAR ONLY IF anatomy is ideal, local graft stock and experience is available.

Need to go to OR. Preparation:

Consent: with pt or power of attorney

- Complications
 - CV, pulm, dialysis, bowel ischemia, leg ischemia, paralysis, need for bowel resection, bypass, amputation, second look lapartomy, blood loss, death.
 - Mortatlity 25-50% in OR.
 - 50% chance of walking out of hospital.

In OR:

- Warm room, body warmer up down
 - Careful when clamped – may cause leg burns
- cell-saver, extra suction, help available.
- preop ABX
- prep nipple-ankles
- induce immediately prior to cutting skin

In abdomen – blood staining of retroperitoneal peritoneum.

- If large inframesocolic hematoma:
 - Will dissect supraceliac axis
 - triangular lig, R lobe liver to R, GE junction to L, dissect R/L crura, arcuate lig incise, position clamp, **don't clamp yet, unless pt is crashing**
 - Then dissect neck, clamp supraceliac if lost control.
- Otherwise, may dissect infrarenal neck directly

Neck 2 cm, got control of iliacs.
Opened sac, bleeding ++.

- Arterial vs venous? Venous - suspect Aortocaval fistula
 - Present in 3-4% of symptomatic, 1% asymptomatic AAA
- Compress IVC outside of the aortic sac above and below defect with sponge sticks.
- Oversee fistula with continuous prolene from inside the aneurysm. Don't dissect it out.
 - No role for IVC covered stent – will cause rupture
 - May consider EVAR for temporizing in florid CHF, unknown hx of IVC type 2 endoleak
 - Expect cardiac output to drop during open repair – compression of IVC
- Allow anesthesia to catch up.
- Check for the status of the IMA - slow trickle.
- Check for Sigmoid - OK.
- Do tube repair. Close sac. Now sigmoid is blue. Woods lamp not available. Ask for doppler - no flow in sig mesentery.
 - check if pt is stable? yes
 - check SMA and celiac circulation AND adequacy of collaterals –
 - on CT stenosis in SMA...
 - check for IMA orifice backbleeding –
 - trickle.
 - Bowel is blue, not black? Blue, bowel may be salvageable...
- then revascularize IMA.
 - Otherwise, Hartmann
 - close sac first, omental cover, sponges with abx, recheck iv dose of antibiotics.

Alternate wording of question:

70 yom, presents 6 h after onset of acute abdominal pain. Was hypotensive, but responded to fluid bolus. Pt has dyspnea, blue swollen legs b/l

DD, Ds?

Ruptured AAA, aortocaval fistula

Management?

Difficulty getting proximal control – what options?

how to repair IVC,

ischemic leg following repair, manage?

Indications for fasciotomy

More than 6 h ischemia?
Signs of myositis or elevated compartment pressure
Inability to monitor limbs (i.e. intubated/sedated)
Concomitant arterial/venous injury (controversial)

36. Middle aged man, presents to ER with hypotension, and left flank pain.

BP 80's. Rupture. Management?

Physical exam – stable. Next?
CT scan done. Provided permissive hypotension supports his mentation.
large bilateral CIA aneurysms.
Left ruptured with large retroperitoneal hematoma.
The internal and external's were OK on the left.
On the right, distal common iliac diameter 2 cm.
What would you do?
Plan to leave R CIA alone, need to fix L
May consider EVAR (iliac extension if high risk pt, excellent anatomy, stable, and able to quickly embolize L IIA if necessary)
Otherwise - OPEN
Next? Needs OR
Detailed CONSENT
accompany patient,
warn the OR
xmatch, warm OR/fluids, conservative fluid, abx
Conduct of operation ie. prepping, induction.
Able to get infrarenal aorta, open aneurysms.
Control back bleeding from iliacs with balloon catheters if unable to get clamp on them
Watch for ureter, bowel, vein etc.
Oversew left internal, bifurcated graft to Left EIA and to the right CIA above bifurcation.
get back bleeding from iliacs.
May need to thrombectomize.
Check feet before closing
Check ureter again, assess belly to see if can close primarily.
Assess need for fasciotomy

37.47 yof, comes in with flank and abdo pain. ER doc does CT – inflammatory AAA.

Approach.

AAA Hx then exam then imaging.

On Hx – flank pain

On exam - Aneu is symptomatic

i.e. pressure on aaa reproduces their presenting sx's (e.g. back pain)

any AAA will be painful if you press hard enough
on CT – pt has inflammatory rind suggestive of inflammatory aneu
juxta-renal
clot in suprarenal a.
general approach to inflammatory:
retroperitoneal approach is preferred
inflammatory rind is not as significant posteriorly
may need supraceliac approach
minimal dissection of the duodenum
repair aneurysm from within...
approach:
Transperitoneal– advantage –get renal control
Disadvantage – head on into inflammatory rind/peel-damage duodenum
Retroperitoneal –
Can get far – suprarenal
Avoid inflammatory rind/duodenum
but poor control of R renal a...

38.Horse shoe kidney and infrarenal AAA

how is your management is going to be affected?
Do angio first to ID renals
In normal kidney, see
20% aberrant (i.e. arteries go to outside of hilum – to poles)
and 10% accessory (i.e. go to hilum)
In horseshoe kidney – all bets are off... total mess
Accessory and aberrant arteries throught the length of the aorta...
May need to do retroperitoneal approach
Pt may have abnormal collecting system
Do not transect connecting lower poles unless sure there is no blood supply compromise or no
parenchyma in the bridge is seen.

Indications for preop angio in AAA repair

- Suprarenal/TTA
- Concurrent visceral reconstruction
- Horseshoe kidney
- Concurrent iliac occlusive disease
- Work up for aortic dissection
- Peripheral aneurysm

What problems does horseshoe kidney pose?

- Accessory renal a off infrarenal aorta

- If blood supply from iliacs- do fast repair
- If blood supply from anterior aorta – may need correal patch/reimplant
 - Difficult to expose infrarenal aorta
- Cut bridging tissue only if fibrous
 - Aberrant collecting system
 - May need to go RP if planning elective repair

39.EVAR: discuss indications, criteria, follow up plan, endoleak management.

When to do EVAR and when open?

When to order angiogram for work up of AAA?

Selection for EVAR:

Anatomic criteria:

<30 mm proximal diameter

15 mm neck

<60 degree neck

No thrombus/calcium

7 mm iliac access

According to Harvard Registry, EVAR has better survival and much better functional outcomes (who goes home and not rehab/nursing home) for all pts across the age spectrum, but particularly so for the older individuals (above 75 yoa). See Minimus notes/tables.

Follow up for EVAR:

CT scan at 1 month, then annually

The purpose of EVAR is to prevent rupture of the aneurysm

early identification of endoleaks is intended to help achieve this goal.

Protocols for managing the different types of endoleak have been suggested

treatment of this complication represents the most common reason for readmission of patients after EVAR.

20% of pts experience endoleak

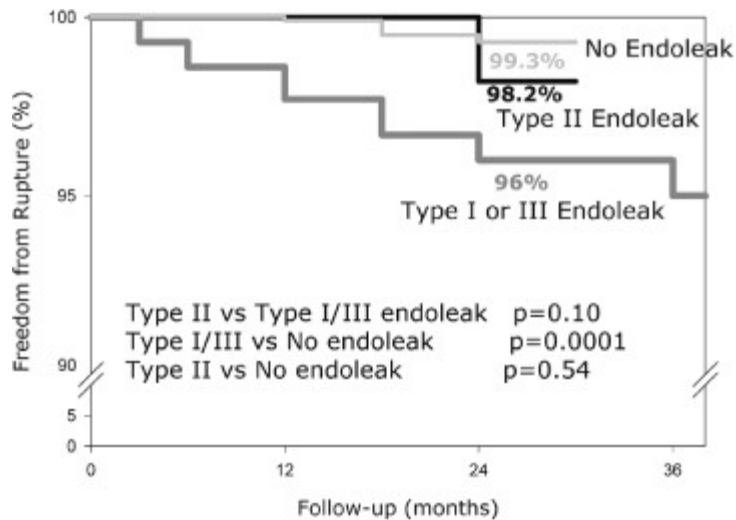
7% at first CT

Most early endoleaks (70%) disappear

13% later

Risk of rupture of type IA/combined with III in EUROSTAR registry (2800 pts) is 1% per year...Or 4% over 3 years....

Still, all type 1 should be fixed: extension vs palmaz vs external banding vs conversion to open



Copyright ©2005, 2000, 1995, 1989, 1976 by Elsevier, Inc.

Freedom from aneurismal rupture after EVAR, categorized by endoleaks presence.

Type II: 40% before 30/7

No risk of rupture with type II if no expansion is seen

No general agreement about the need for graft related interventions in pts with endoleaks

Controversy re: most appropriate type of intervention for type II.

Coil, glue, laparoscopic/open clipping vs observation

Type 2 with sac shrinkage

No intervention, continue follow-up

Type 2 with sac expansion

Seen in 10% of cases

Most will recommend intervention

Sac expansion → migration & distortion of fixation sites → type I/III leak → increased risk of rupture

Type 2 with stable sac size

Controversial

Safe to observe according to Silverberg et al...

Sack enlargement is seen in:

in 20% of patients with type I/III endoleak

In 10% of patients with type II endoleak

In 5% with no endoleak

Aside: EVAR complications - EARLY

- Radiation exposure to pt and personnel
- contrast allergy
- renal failure

- Access trauma:
 - perf, dissect, thrombosis
 - Microembolization of plaque or AAA thrombus
- Graft displacement or misplacement
 - Occlusion of RA, IIA, SMA
- Endoleak
- Postimplantation syndrome
 - fever
 - backache
 - malaise
- graft limb compression
 - thrombosis, stenosis, occlusion

LATE

- Graft migration
- Endoleak
- Limb stenosis, kink, thrombosis
- AAA rupture

40.Type III leak in aneurysx graft placed several years ago. Management?

Either open (take out graft) or reline
 AUI and fem-fem with new generataion impermeable stent

41.Cancer Renal cell carcinoma and 6cm AAA.

When would you not fix aneurysm?
 If palliative and limited life expectancy
 Need risk of dying because of surgery and cancer combined less than risk of rupture over the next 2 years...
 i.e. Need at least 2 years
 Met Ca, pancreatic cancer – presence of these conditions allow to forget about repair
 Options for repair of both problems?
 medial visceral rotation

42.Large AAA and iliac occlusive disease.

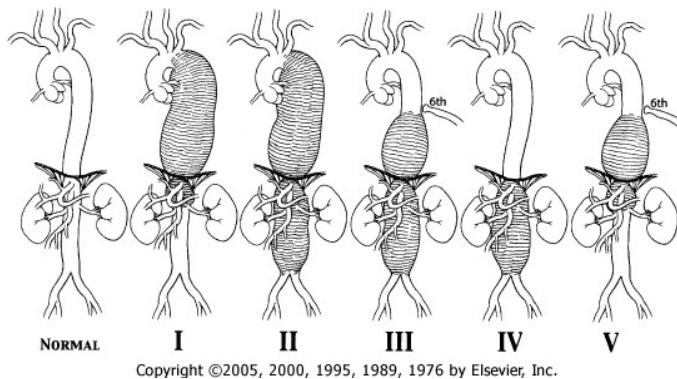
Femorals open. Occluded R external and open R internal and IMA.
 Choice of procedure?
 ABF end to end (because of aneurismal disease)

To keep flow to iliac and IMA may need to reimplant IMA and/or R internal iliac onto the graft...

43.Type III Thoracoabdominal aneurysm:

Work up, surgical approach, measures to prevent renal and spinal cord ischemia.

Thoracoabdominal aneurysm (TAA)



- High-High, High-Low, Low-Low, Very low, in the middle.
- Think of a giant slug sliding down in stages (1->4) then climbing back up...
 - Renals are spared in 1 and 5
 - These are similar, except 5 starts below 6th rib
 - 2 and 3 are similar
 - Except 3 starts below 6th rib
- Most are degenerative, like infrarenal
 - Thinning of media, destruction of SMC & elastin
- 20% have family history
- Syndromes associated TAA:
 - Marfan (MC)
 - Familial – 75%
 - New onset – new mutation 25%
 - Turner
 - Ehlers-Danlos
 - Polycystic Kidney
- Dissection (20% of TAA)
 - Up to 40% of aortic dissection end up in aneurysm at 7 years
- Infection/trauma (minority)
 - Salmonella, H.Flu, Staph, TB, Treponema
- Presentations:
 - Asymptomatic

- Compression:
 - Lung, esophagus, RLN, duodenum, stomach, ureter
- Rupture
 - Into duodenum, appendix, ureter, peritoneal/pleural cavity
- Athero-embolic event into limbs and viscera

Aside:

Rupture of an arterial vessel results in sudden hypotension that is quickly relieved with minimal fluid replacement (rupture of a unicameral system, Frances Moores). Hence, phenomenon of stability after initial rupture of AAA.

Hypotension due to venous bleed occur AFTER significant bleeding took place and requires significant replacement.

- Predictors of rupture:
 - Size > 7 cm
 - 1cm/year expansion
 - HTN (diastolic)
 - Smoking
 - COPD
 - Gender (F>>M)
 - Age – up 2.5 folds for every decade
 - For >70 yoa, 50% risk of rupture within 1.5 years
- Treatment options:
 - Open (traditional)
 - Clamp and sew
 - Distal perfusion & sequential clamping
 - Endo (branched & fenestrated)
 - Hybrid
 - Debranch & stent
- Risk of repair:
 - COPD
 - RF – if have RF with Cr > 180 (>2) – poor prognosis for repair

	Type 1	Type 2	Type 3	Type 4	Overall
Renal failure	7%	12%	11%	9%	7%
paralysis	6%	29%	11%	2%	13%

Assess risk of rupture, operative fitness, longevity...

Strategy for renal protection:

Goals: reduce renal oxygen use, reduce direct renal tubular injury, maintain perfusion

- Hold nephrotoxins (ACEI, aminoglycosides)
- Distal aortic perfusion
 - Only protective when renal a. do not require reconstruction
 - i.e. for type 1 and 5...
- Selective visceral perfusion
 - Does protect the liver
- Retrograde hypothermic renal venous perfusion to 15 degrees
 - But keep core body temp at 32-33 degrees

So far, none of these techniques have been shown to definitively reduce incidence of RF

Spinal cord protection methods during TA repair:

Reduction from 6.6% to 2.4%

- for descending Aortic Aneu – 0.9%,
- for TAAA – 3.3%

Overall, these results cannot be duplicated outside centers of excellence (Safi et al)

- Distal aortic perfusion
 - Passive (Ax-fem, Gott shunt)
 - Active
 - a. L atrial-fem bypass
 - b. Complete cardiopulmonary bypass
- Perioperative CSF drain
 - Spinal cord pressure= MAP – CSF,
 - keep CSF pressure at <10 mm Hg
 - keep MAP up
 - drain 10-15 cc/h
 - d/c drain on POD 3
- Intercostal aa. Reimplantation (T9-L2)
 - Artery of adamkowitz – 75% T9-L2, 15% T5-8, 10% L1-2
- Expeditious operation
- Other
 - Hg >100
 - CI >2
 - MAP 90-100
- Aside: for visceral organs, selective perfusion +/- organ hypothermia
- Pharmacology

- Nalaxone
 - Steroids
 - Magnesium
 - Calcium channel blockers
 - Oxygen free radical scavengers
 - Barbiturates
- These have not shown to be consistently protective
- Hypothermia
 - Spinal (4 degrees C)
 - systemic
- spinal ischemia may have delayed presentation (see in 3% of pts):
- if this is seen, prompt drainage, maintenance of BP (CI >2) and treatment of anemia is key.
- **If drain is reinserted at the onset of symptoms – 75% recover, if during full blown deficit – 40% recover.**

44. Type IV TAA, b/l renal a. stenosis (severe) in hypertensive 65 yom.

Need to fix AAA and renals:

See renal hypertension notes.

Options:

STANDARD approach:

Suprarenal clamp, repair AAA incorporating orifice of both renal arteries in the proximal anastomosis.

SOMEWHAT uncommon:

Extra anatomic (off supraceliac or hepatic) –

Debranch then stent

do renal artery bypasses first,

then deal with AAA.

This will allow to decrease visceral ischemia and minimize aortic clamping type to the minimum

Weird and wonderful: open version of complete debranching...

Ax-fem first

Sew 4 6 mm grafts onto the body bifurcated AAA graft (for visceral vessels)

Do iliac anastomosis first to the AAA graft,

Clamp proximal ends of the 6 mm grafts and do individual bypass from reperfused AAA graft

do proximal anastomosis going up the SMA.

No good access to proximal anastomosis,

Very cumbersome if SMA and celiac need to be debranched

Problem with kinks...

AORTIC DISSECTION

45. Classification and management of aortic dissections.

Classification:

Sandford (S for simple) –

A - ascending,

B – descending

3:2 = A:B

More in men

DeBakey classification (D for difficult)

1 origin in ascending, goes at least as far as the arch or further

2 origin in ascending, limited to ascending

3 a – origin in descending, limited to descending

3 b – origin in descending, goes to abdominal

3 c – origin in descending, goes proximally to arch

	Type I	Type II	Type IIIa	Type IIIb	Total
Number of patients	194 (38%)	84 (16%)	112 (22%)	122 (24%)	512
Male/Female	137/57	61/23	62/50	87/35	347/165
Age (mean)	60.1	56.4	67.7	63.5	62.0
VC	86 (44)	10 (12)	9 (8)	54 (44)	159 (31)
HBP	121 (62)	47 (56)	91 (81)	102 (84)	361 (71)

Copyright ©2005, 2000, 1995, 1989, 1976 by Elsevier, Inc.

Treatment of type B aortic dissection:

Medical –

- impulse control with BB/dilators is mainstay
- better survival rate with medical therapy (instead trial, irad)
- goals of treatment:
 - Stabilize extent of dissection
 - Reduce intimal flap mobility
 - Relieve dynamic aortic branch obstruction
 - Decrease risk of rupture
- Ultimate goal:
 - Induce aortic remodeling through FL thrombosis

Canadian Vascular Surgery In-Training Cases, U of Ottawa, Anton Sharapov, MD, 2008

- Indications for surgery
 - Rupture
 - Or imminent rupture manifested by
 - Recurrent pain
 - Rapid aortic expansion
 - <4% of acute presentations,
 - 20% during the course of disease
 - Branch Vessel occlusion
- Malperfusion seen in 25-40% of acute dissection
 - Most important source of M&M
 - Diagnosis and management are delayed
 - 50-80% mortality if renal ischemia
 - 87% if mesenteric ischemia
- mortality for open surgery for malperfusion > 20%
- Hence endovascular option is attractive
 - 80% are dynamic occlusions – hence controlled with thoracic stent over entry hole, 20% of static may be amenable to direct stenting...
 - Hence reduced upfront M&M
- **Options:**
 - Open
 - Central aortic replacement – for rupture (used very rarely)
 - Open fenestration for branch occlusion (used rarely)
 - Out of 800 type B AD in Cleveland series, only 14 were managed with open surgery, 7 acute and 7 chronic...
 - White knight on a white stallion in the middle of the night operation
 - Heroic measures
 - Principle:
 - Wide resection of the dissected septum
 - Equalize flow through both luminae
 - 9-10th IC space thoracoabdominal exposure
 - Septectomy may be extended into visceral vessels
 - If small aorta/poor flow/suspected osteal obstruction
 - Resect septum
 - Inspect/tack peri-osteal intima
 - Fenestrate to infrarenal level with Teflon pleget
 - Replace infrarenal aorta with distal double-Teflon pleget anastomosis
 - Endo
 - Entry site sealing
 - Endo fenestration
 - Problem with endo:

- Endovascular approach only seals endoluminal source of bleeding
 - Large vasa vasorum and intercostals may still contribute to late rupture/growth
 - May not provide long-term survival benefit
 - Bridge therapy through rupture/emergency situation?
 - Surveillance necessary
- **Conclusion:**
 - For uncomplicated type B – medical therapy
 - For complicated – consider expeditious diagnosis and treatment
 - Rupture will likely require open repair
 - Stent if local expertise/logistics available
 - IF significant comorbidities – consider stent
 - Stent entry point and enlarge true lumen if dynamic branch obstruction. Consider fenestration if no outflow for FL
 - Stent individual branches/or individual vessel orifice if static obstruction
 - Consider open if failed
 - Septectomy through RP
 - Carefully follow chronic dissections for future TAA
 - 14% at 4 years
 - 40% at 7 years

46. Man came with sharp shifting sudden back pain. New onset. Management.

- ABC - protects airways, good oxygenation/breathing, hypertensive, tachy.
- Stabilize then proceed with the rest of story
- Hx of connective tissue disorder/cocain/aortic surgery/heart valve problems
- Hx of PVD factors
- previous similar attacks
- ROS:
 - CP, nausea, heartburn, writhing, alcoholism, SOB/cough, back problems, relief with anterior tilt
 - I.e. check for other problems that cause this presentation:
 - MI/eso/duo/gasric perf/pneumonia/pericarditis/back problems
- Dissection effects – signs of complications...

- extremity pain/weakness/coolness, abdominal pain, melena, decreased urine output
- Meds: recent change in meds (clonidine dc)
- o/e:
 - pressure, pulses - arm/leg inequality, abdo pain/peritonitis, UO via foley. Marphanoid status, skin elasticity
- imaging - in ER esophageal ECHO or CT with contrast.

Scenario 1:

- hypotensive, sudden onset - likely type A
 - in type B, less than 5% in presentation is acute hypotension
- need to sort out rupture in B vs pericardial tamponade in A –
 - hence ask for stat Echo/fast or do pericardiocentesis/pericardial window
 - Then emergent cardiac surgery

Scenario 2: uncomplicated B - management

- Anti-impulse therapy
 - with control of myocardial contractility/HR (BB) first,
 - then afterload reduction (Nitroprusside)
- if pain not settled - image –
 - if evidence of rupture or size increase - need intervention.
- MAP
 - keep it less than 70.
 - Just keeping systolic < 120 (110 for Marfan) is not enough – need to follow MAP

Surgery indications:

- for rupture (<5%),
- for rapid growth (pre-rupture) – 20% of all type B
- for visceral branch obstruction –
 - peritonitis (SMA involvement)
 - CT evidence (any visceral branches)

Options:

- Central aortic replacement plus open fenestration if rupture. high mortality/morbidity
- If near rupture - stent entry point first
 - to prevent back extension then prop open true lumen
 - Works best for chronic dissections.

- If dynamic obstruction –
 - do endovascular US, evaluate flaps, do endo flap fenestration (scissors vs U pull down)
- if static obstruction - do stenting
- If not relieved, then open, and do debranching without touching aorta - bypass to compromised vessel..
 - Aorta is raw and friable...
 - Another alternative – open septectomy

AORTA – INFECTED ANEURYSMS, GRAFTS, ETC

47. Elderly female with sudden, severe CHF.

Found to have bacterial endocarditis with vegetations on mitral valve. Growing E.coli in blood. Also noted to have saccular aneurysm distal aorta on CAT scan. Asymptomatic. Approach.

On hx:

- AAA questions
- Infection questions:
 - IV drug use? (if young)
 - Hx or Rheumatic fever
 - Melena/GI bleed after previous AAA repair
 - Systemic sxs
- Examine for murmurs, splinter hemorrhages
- Lab: Echo, cultures
- Ds? Valvular insufficiency, bacterial endocarditis, mycotic aneurysm.
- Patient is septic from BE. What needs to be done?
- Treat CHF
- Consult ID for abx
- discuss with cardiac surgery
- need to fix valve first, control sepsis.
- patient is asymptomatic from her AAA
- AAA is saccular - suspicious for mycotic aneurysm
- DD of mycotic aneurysm?
 - Infected existing, microbial arteritis with aneurysm, mycotic
- What are the findings on CT?
 - Wall thickening
 - Vertebral osteomyelitis

- May be collection of fluid
- Loss of tissue planes
- Saccular aneu
- Multilobulated
- Eccentric aneu with narrow neck
- What findings see on angiography of infected aneurysm?
 - saccular aneu in normal vessel,
 - multilobulated aneu,
 - eccentric aneu with narrow neck
- Patient had her valved fixed. Now what?
 - Patient is still asymptomatic.
 - continue to wait: She is elderly, critically ill.
- Patient then develops tender AAA.
 - If previous size of AAA was large – then fix, otherwise, repeat CT.
 - If truly symptomatic, need to fix regardless of size...
- You need to operate – approach?
 - bilateral ax-fems, then deal with her infected aorta.
- principles of dealing with infected aorta.
- Option other than extraanatomic bypass
 - insitu replacement, autogenous vein graft repair, EVAR with antibiotic suppression for life

Aside:

	MYCOTIC ANEURYSM	MICROBIAL ARTERITIS	INFECTION OF EXISTING ANEURYSM	POST-TRAUMATIC INFECTED FALSE ANEURYSM
Etiology	Endocarditis	Bacteremia	Bacteremia	Narcotic addiction, Trauma
Age	30-50	>50	>50	<30
Incidence	Rare	Common	Unusual	Very common
Location	Aorta	Atherosclerotic	Infrarenal	Femoral
	Visceral	Aortoiliac	Aorta	Carotid
	Intracranial	Intimal defects		
	Peripheral			
Bacteriology	Gram-positive cocci	<i>Salmonella</i>	<i>Staphylococcus</i>	<i>Staphylococcus aureus</i>
		Others	Others	Polymicrobial
Mortality	25%	75%	90%	5%

- Post traumatic infected false aneurysm – MC
- Microbial *Salmonella* arteritis with aneurismal degeneration - common

Canadian Vascular Surgery In-Training Cases, U of Ottawa, Anton Sharapov, MD, 2008

- Infected pre-existing aneurysm - unusual
- Mycotic aneurysm (preantibiotic >90%, now <10%) RARE

Does not include:

- **infection from contiguous source**
- **aorto-enteric fistula**
- **vascular synthetic graft infection**
- **see different sections**

- **Mycotic: mortality 25%**
- Due to endocarditis
- 30-50 yoa
- Location:
 - Femoral 89%
 - Upper ext 13%
 - aorta 12%
 - Cranial 4%
 - SMA
- Where – bifurcations, AVF, coarctations.

- Microbiology:
 - if no IVDU – Strep Viridance 22%, SA 20%
 - IVDU – SA 36%, Ps. Au 16%

- **Microbial arteritis with aneu: mortality 75%**
- 50 yoa
- Due to bacteremia
- More common than mycotic
- At the site of Atherosclerosis
- Also, AIDS, CRF/hemodialysis pts are susceptible
- Most commonly aorta (3:1 compared to peripheral sites)
- **77% of all infected aortoiliac aneurysm...**
- Most common E.Coli, **Salmonella – predisposition to Aorta, SA**

- **Infected pre-existing aneu: 90% mortality**
- 15% of all AAA grow microorganism – unknown significance
 - 38% ruptured
 - 13% symptomatic
 - 9% elective
- Microorganism:
 - Staph – 41% - St. Epi is most common

- **Post traumatic infected: 5 % mortality**
- Most common, lowest mortality
- IV drug abuse
- After percutaneous procedure - RF:
 - Long procedure
 - Repeat cath
 - Difficult access
 - Arterial sheath in >24 h
 - CHF
 - Use of angioseal device
- Most common micro – Staph Aureus.
 - Fungal RARE – in DM and immunosuppressed.
- Presentation: difficult to detect.
 - Fever of unknown origin
 - Positive blood culture
 - Erosion of lumbar vertebrae
 - Female sex
 - Presence of uncalcified aneurysms
 - First presentation of an aneurysm after bacterial sepsis
- If see aortic infection – likely microbial arteritis leading to aneurysm
- If see femoral infection – likely infected pseudoaneurysm, second possibility - mycotic aneurysm
- Culture studies...
 - Negative blood cultures, intraoperative Gram stain
 - ARE NOT sensitive enough to exclude ds
 - In Ruptured infected AAA, only 69% of blood cultures and 50% of Gram stain are positive
 - Gm stain only 11% in non-ruptured infected aneurysms are positive
 - Even in aneurysm wall culture was found to be positive in only 92% ...
 - p.1588
- angiography appearance:
 - saccular aneu in normal vessel,
 - multilobulated aneu,
 - eccentric aneu with narrow neck
 - Lumbar osteomyelitis
- Indium -111 labeled WBC helpful for prosthetic graft infection, NOT infected aneu...
- **Incontrovertible principles of treatment:**

- Control hemorrhage
- Confirm ds: gram, culture for bacteria/fungi/TB
- Operative control of sepsis: resect, debride, abx irrigation, drain
- Post op wound care: dressing change, repeat debridements
- Long term abx
- Consider reconstruction through non-infected field: *THE ONLY TENET OPEN TO CONTROVERSY...*

48. Infected ABF case....

- 79 yom
- ABF in the past 2 years ago
- presented with draining R groin, purulent, previously well

Assess :

- local circumstances:
 - how did groins open up
 - steroids, cancer, chemo, poorly controlled diabetes, scurvy in alcoholic
 - when/how much drainage
 - how treated/abx/culture/redness/swelling,
- PMH: other surgeries, indications for original ABF, recent infections
- General specifics : melena, abdo pain

- PVD factors and management,
- ROS including mobility, nutrition, CV status, and claudication.
- systemic (fever/chills/sweats/wght loss/sleep etc),

- Meds/allergies

Full exam:

- BP, HR, pulses, masses, ABIs, groin - mass, no blood, CS/gram.
- distal petechial hemorrhage.
- Hypertrophic osteoarthropathy

Pt has had no abx, has 5 block claudication, drainage for 2 month, normal exam, except sinus in R groin. Fever. Tachy. Approach?

- Admit, IV antibiotics, fluid resusc, BW (cbc, esr, blood culture, u/a, lytes/Cr), CXR
- CT with IV contrast only.
 - Assess if graft is functional and working
 - Assess runoff
 - Assess extent of infection

- **Obtain and review old charts. OR reports**
- What am i thinking?
 - R groin infection – graft may be involved.
 - Source:
 - Local seeding at operation
 - Hematogenous seeding from other source
 - Erosion into GI tract
 - tracked from abdominal portion of the graft
 - GEE/GEF, evaluate duodenum adherence
 - Contiguos spread
 - other infection source secondary to perf Ca/psoas abscess/TB/lymphoma/etc.
- CT shows:
 - R limb fluid up to the bifurcation and loss of tissue plains.
 - R groin collection.
 - B/L native EIA occlusion, IMA gone,
 - but both internal iliacs open.
- Approach?
- Optimize
 - anesthesia, malnutrition, culture, ABX specific to culture
- Temporize: drain abscess percutaneously and culture
- Prepare for surgery
- Detailed consent discussion

Surgery:

- If unstable - immediate explant.
- If stable, stage revascularization 1st, then explant
- Gold standard –
 - extra anatomic bypass followed by graft excision,
 - management is tailored to
 - original indication for surgery
 - type of original reconstruction (End to End or to Side)
 - what pt can withstand
 - current PVD status, fitness, degree of disability
 - what microoragnisms grew
 - presence of sepsis
 - virulence

- type of graft and extent of involvement.
 - pt may not tolerate large procedure.
- options :
 - remove graft, oversew aorta prox and distally
 - This is most commonly applied option
 - may need to revasc kidney if stump is inadequate
 - +/-revascularize limbs
 - Other options:
 - patch femorals (and aorta if graft End to Side)
 - Bilateral ax-unifem to profunda
 - in situ replacement:
 - SFV, PTFE, allograft, Dacron with abx **if biofilm only**
 - patch fem and aorta and endovascular:
 - recanalize iliacs (endo) – but this is type D Tasc II lesion...
- Specifics of OR:
 - discuss complications
 - limb loss, dialysis, stump blowout, hemorrhage, colon ischemia, wound infection, patch blowout, new graft infection, paralysis, need post op abx.
 - find out micro organism, IV abx coverage,
 - sort out outflow (order angio if necessary)
 - DECIDE between:
 - explants +/- revasc,
 - preservation of the graft
 - for biofilm infection
 - for complex thoracic reconstruction
 - insitu replacement
 - Explantation is SAFEST way of treatment
 - total explant
 - Ideally preceded by extraanatomic revascularization
 - first do ax-uni-fem bilateral
 - not bifem - avoid crossing the midline
 - will need to take out the graft to profundas or popliteals
 - Tunnel laterally
 - Take out a notch in the iliac crest and nestle the graft in it
 - to keep graft from slipping medially
 - This will also prevent graft from kinking.

- Graft preservation or Insitu replacement possible but risky, may consider SFV

Conduct of OR: total explants

- Review old OR records
- open groins first, control native arteries
 - dismantle anastomosis
 - debride tissues, wash with ABX
 - decide on ligation of artery vs patch reconstruction
 - If patching, must have clean artery
 - do vein patch - will preserve iliac flow....
 - do intraop culture and gram.
 - **muscle coverage +/-VAC,**
- abdominal portion of the procedure:
 - with infrarenal clamp - if necessary supraceliac
 - close stump in two layers monofilament, locking,
 - If ligation close to renals –
 - may choose to ligate renals and accept possibility of dialysis
 - BAD course of action...only in very HD unstable...
 - Better to bypass renals with vein (debranch) then have more aorta to close.
 - cover with anterior spinal lig or omentum,
 - close the other side of aorta distal to graft,
 - pull out graft from retroperitoneum,
 - debride/pulse irrigate
 - leave suction drainage,
 - re- assess L colon/sigmoid (if both iliacs are gone).
- **Alternatives:**
 - *IF sure that only Groin is infected...*
 - One limb explants only –
 - only if biofilm infection –
 - confirm with intraop GRam stain – should be negative for other bugs..
 - 1st transect graft in clean plane - either through Retroperitoneal incision, or through abdominal approach,
 - Groin exploration – pull graft out
 - Common femoral – decide between Patching vs ligation
 - Ideally preserve bifurcation

- Revascularize the limb...
 - Revascularisation can take place via lateral (ax-profunda) or medial (obturator, fem-fem) bypass.
 - *patch closure & endovascular recanalization of the existing iliacs*
 - May be dangerous as may need to put stents up through infected fields

Aside:

Technique of obturator-femoral bypass:

- Inflow from iliac – contralateral or ipsi
- Dissect medial to iliac vein on the R and Lateral on the Left, below superior pubic ramus
- ID obturator membrane
- Obturator n. and a. are in *posterolateral aspect*
- INCISE *anteromedial portion* of the membrane
 - Tough membrane – don't try to ram it through
- Enter the plane between adductor magnus posteriorly and adductor brevis/longus
- Tunnel distally to SFA or popliteal

Selection of pts for infected graft preservation:

- No sepsis
- No pseudomonas
- Not Dacron
- No anastomotic involvement
 - Note: Dacron may still be preserved but less chance of success compared to PTFE

Selection of infected graft for insitu replacement:

- No sepsis
 - No positive blood and tissue cultures
 - Biofilm culture positive for Staph Epi
- No graft-enteric- fistula
 - TRADITIONALLY No graft-enteric- fistula BUT:
 - thoracic aortic replacement has got to be insitu
 - good results have been achieved with abx bonded and SFV
 - 70% of primary AEF are sterile.
 - Still, for exam purpose this technique is dodgy...

How to preserve the graft or do in-situ replacement:

- IV abx broad range
- Pretreat for several days

- Sterilize field locally:
 - Debride
 - Dismantle graft if decided to do insitu replacement
 - If preserving – leave graft in place
 - Irrigate
 - Vanc/gent beads q 7 days
 - 1% iodine saline dressing
- Confirm sterilization on culture
- If replacing in situ:
 - Vein or PTFE- rifampin soaked graft
 - Gentamicin impregnated thrombin glue on anastomosis
- Muscle flap
- 6 weeks iv abx then 3 months po antibiotics minimum
 - Consider life-long suppression

49. Patient with previous AAA graft repair. Has Upper GIB.

Stable, melena stool.

CT scan- air and fluid around graft, no tissue plane between the aorta and duodenum.

Plan:

Rule out other source of bleed: scope

Establish diagnosis of infected graft

Antibiotics, then bilateral ax-fems, then graft removal, debridement etc.

Other options? In-situ replacement, vein graft repair, endograft?

These may be mentioned on exam as alternatives recognizing their non-traditional nature

Otherwise old farts might freak...

CT findings of aortoenteric fistula:

- Periaortic gas or fluid
- Proximal pseudoaneurysm formation
- Bowel wall thickening
- Retroperitoneal stranding
- Plane between duodenum and aorta obliterated
- IV contrast seen in bowel

Selection of pts for infected graft preservation:

- ALMOST NEVER POSSIBLE IN Aorto-Enteric fistula in EXAM setting.....
 - Unless you are Dr. G. Claggett...

Results of aortic graft infection treatment:

- Staged (ax-fem first, then in 2 days excision of aortic graft) is best
- Don't use synthetic pledgets on aortic stump – nidus for infection
- If ax-fem got infected, then consider need for revasc...

- If see monophasic signal or > 40 mm Hg at ankle, may consider forgoing revascularization
- if ischemic, then may do thoracic-fem bypass

	Mortality	Amputation	Re-infection	Survival > one year
Ex-situ bypass & excision	20%	15%	10%	80%
In-situ with vein	10%	5%	1%	80%
Rifampin PTFE in situ	10%	5%	15%	85%

Note, for infected aortic explants (i.e. not AEF), mortality is 12%, amputation is 7%, need for revision is 29%, aortic blowout is 2%.

Aside: Aorto-enteric fistula

Primary

Less common

Degenerative sterile AAA expansion most common.

Duodenal Ulcer (second MC)

Cancer, FB

Secondary

Infection at suture line

leads to pseudoaneurysm, expansion, pressure on the duodenum

Infection likely latent –

skin flora that gets activated with dips in immunocompetence (p. 904)

Pulsatile pressure is a factor

Duodenum – injury during Transabdominal mobilization

Historically, original fistula were at the body of the grafts when homografts were used

Manifestation:

GI bleed, sepsis, abdo pain – rare

GI bleed – seen in 21% of all AAA repairs,

But only 0.4% of UGIB in AAA setting will have AEF

Fever/malaise

Septic emboli

Common – 27%

Multifocal osteomyelitis

Hypertrophic osteoarthropathy

Abdo pain due to pseudoaneurysm pressure

Evaluation

Canadian Vascular Surgery In-Training Cases, U of Ottawa, Anton Sharapov, MD, 2008

Hx and physical

UGI bleed, lower GI bleed (aortoappendicial fistula/to limb), AAA repair, systemic signs, abdo mass, LE multifocal cellulitis

EGD – to r/o other source of bleed, to 4th portion

CT

Indium 111 scan

Angio to define run off and renal a. location

In half the cases need to explore in OR to establish diagnosis definitively

Treatment is surgical:

ID presence of active hemorrhage

Classify AEF – primary vs secondary

Presence of AIOD vs aneurysm

Extent of sepsis

Goals:

Save life, then preserve limb. How:

Control hemorrhage

Control infection

Repair GI tract

Maintain adequate distal perfusion

Surgery: DETAILED consent first: honest, realistic, detailed...

Scenario 1: pt is bleeding:

lines/abx/emergent surgery

TP vs retroperitoneal

RP if difficult neck is anticipated,

can't see R CIA, R renal and can't do Right ax-fem

Supraceliac control of bleeding first – place clamp but don't close it until needed

Medial visceral rotation vs through the crus

Distal control

Peel of duodenum, put a stitch to control spillage if needed

Resect/debride infected aorta

Triple closure of stump:

Interrupted horizontal mattress

Running locking

Omental tongue/anteriotibial lig

May not have enough stump – revascularize renals first

Decide on in-situ vs extra-anatomic

Repair duodenum:

Primary, roux-en-y, +/- gastrostomy, jejunostomy

Assess extremities

If monophasic signal/>40mm Hg at ankles may forego revasc

Scenario 2: No bleeding:

Confirm diagnosis AND rule out GI bleed (other sources)

CT, EGD, tagged RBC, WBC scan

Consider extra-anatomic revascularization first prior to excision.

Variation: while doing bypass, pt develops bleed and needs conversion to laparotomy and bleeding scenario.

If primary AEF – only 30% are infected

May consider in-situ repair with life long surveillance

Possible if minimal retroperitoneal soiling and no sepsis

Allows for simple durable revascularization

Uncertain long term potential for infection

Safer option is an extra-anatomic repair

Bacterial seeding in AEF can occur in about 25% of all the EAB...

For typical synthetic graft, the risk is about 10%...

In situ: use 1200mg rifampin in 20 cc NS, soak 15 min

In situ may be the most expedient technique if pt is unstable and don't have enough aorta to do solid stump

Culture, in situ and get out – may come back for interval renal revascularization and stump creation when pt is stable if cultures are fungus or gram negatives.

Composite extra-anatomic bypass –

SFV to infected groins, prosthetic to axilla... any merit? P.910

Role of EVAR?

Limited... may be considered for primary

AEF after EVAR has been described as well...

Results of Aorto-Eneric fistulae repair:

Natural history – bleeding, sepsis, death

Operative repair -30-40% mortality

Amputation 10%

3 year survival 50%

50. L groin mass and pain 5 years after ABF:

Onset, duration, progression of symptoms

Fever/bleeding/ Claudication/drainage

Groin pulses, distal pulses, stigmata, ABIs

Routine labs, blood culture, US,

if collection and no flow - guided aspiration for culture, start broad spectrum abx

CT scan abdo/pelvis

Involvement of main trunk ?

Involvement of anastomosis?

Arterial Run off

Surgery:

Explore groin first:

Anastomosis not involved –

drain abscess, debride aggressively, tissue coverage with Sartorius flap, life-time of abx..i.e.

preserve graft

Contraindication to preservation:

Dacron (relative)

Pseudomonas infection

Anastomotic involvement

Graft occlusion

Presence of sepsis

70% success with this technique

Anastomosis involved –

Debride and remove graft

New In situ graft vs extra-anatomic reconstruction

Indication for in situ replacement:

No sepsis

Staph epi in biofilm

No positive cultures

No aorto-enteric fistula

Send excised graft for culture, specify to sonificate (to get S. Epi out) the graft and use broth culture (not agar) – improves yield from 30% to 70%.

Variation of scenario: 4 weeks post ABF, wound never healed.

51. Young male after intra-arterial injection.

2 scenarios – CFA and brachial artery. Approach and treatment.

ID if dealing with infected site of injection. If infected:

hx, exam, US,

indium scan – not very reliable in the setting of infected pseudoaneurysm

Abx first, culture, imaging

May need ligation

both brachial and CFA can be safely ligated

preserve bifurcation

ID distal damage and extent limb ischemia (pain, sensory/motor loss)

Commence treatment (see notes)

Notes:

Present with acute pain, sensory loss, most severe changes seen distally.

Cool mottled fingers, reduced motor function.

pulses present
contour may be more pronounced due to outflow obstruction

Complications of intra-arterial injection:

Arterial vasospasm
Arterial/venous occlusion
Intimal damage
particles, infection, intense inflammatory response
Atheroembolism
Infection
Artery wall
Soft tissue (cellulitis/abscess)
Pseudoaneurysm

All these may lead to mycotic aneurysm formation, pseudoaneurysm, gangrene and chronic ischemia.

Treatment:

Once intravascular damage occurs, limited role for bypass
Goal – preserve collaterals, settle inflammation/edema
Heparin, keep ptt 2 times normal (n=20-40 sec)
Dexamethasone – 4 mg iv q6h for inflammation
Dextran 40 20 ml/h – to keep platelets aggregation low
Pain control, elevate – to reduce edema
physio to minimize contraction
continue this for 3-7 days or until resolves
role for tpa undefined
defer debridement until later on

mycotic aneurysm:

can safely ligate brachial a, CFA, SFA, Profunda
if CFA bifurcation is affected, then incidence of ischemia is significant
broad spectrum ABX -> culture specific
cover with flap
frequent dressing changes/abx/debridements
observe for ischemia
consider revasc through clean tissues at a later date

pseudoaneurysm:

if not infected, compression with US +/- thrombin injection
won't work in obese, on anticoagulation
contraindicated with skin necrosis, tenderness over mass, neuro symptoms
open:
gold standard method of treatment

indications:
failure of above methods
Suspected infection
Evidence of vascular compromise
Ongoing/imminent hemorrhage
Skin erosion
Relative
Neuro compromise
anticoagulation

CAROTID STUFF:

52. 60 yom with L TIA. Unremarkable H&PE

Ensure HD stability, no HTN and any ongoing neurologic abnormality
If no - take routine hx and perform full PE

On History:

- duration, frequency, character
- motor, sensory, speech, coordination, movement
- aphasia vs dysphasia
- change in LOC, headache, vomiting, seizures, neglect
- handedness

- Documentation of previous episodes

- RF for ASC (htn, dm, lipid, smoke, obesity), AF
- Recent trauma

- Illicit drugs
- rads to neck,
- personal or FHX of vasculitis, CTD

- prev studies of neck (CT/US), known carotid disease.
- Meds: antiplatelet (recent changes), lipid, htn (acei, bb, diu), anticoagulants
- PMH, surgery,
- ROS: Intermittent Claudication, Chest pain, recent MI

Patient is well, no lipid meds, no HTN meds. no smoker

oe:

- neuro status and full neuro exam
- orientation, coordination/balance/movement,
- speech
- dysarthria – R hemisphere source
- aphasia – L hemisphere source
- side neglect,
- disability neglect,
- CN

- motor/sensory/reflex,
- Power
- DTR
- plantars

BP both arms, HR, temporal pain, retinal exam, neck bruit, HS, AAA, splinter hemorrhages, distal pulses, stigmata of PVD

mild L sided weakness. nil else

Aside: Mechanisms of stroke? Based on Rutherford

- Ischemic (80%)
- hemorrhagic (20%)

Ischemic:

- 20-30% are due to major Extracranial and intracranial cerebral vessels
- 30% are due to embolism (close to 50% in pts younger 40 yoa)
- 40% of stroke – no known cause

Strokes happen because of:

- Embolism
- Thrombosis
- Hypoperfusion

Pathology leading to stroke:

- Atherosclerosis 90%
- Artery-artery atheroembolism (MC)
- thrombosis

- Embolism – more common than carotid pathology
 - Cardiac (AF, post MI, valve)
- Other:
 - FMD
 - Kinking
 - Intimal dissection & traumatic occlusion
- Vasculitis (Takayasu, GSA)
- Aneurysm
- Intracranial vessel disease:
 - CTD – sclera, sjogren, SLE
 - Lacunar infarcts,
 - Vasculitis:
 - PAN, GCA,
 - Other arteritis
 - allergic, granulomatous, infectious P. 1883
 - moyamoya, fibrinoid necrosis, amyloidosis,

Blood work:

- cbc (plt, RBC),
- Cr,
- gluc, HgA1C,
- lipid profile,
- ESR,
- fibrinogen, homocystein,
- PT/PTT/INR
- drug screen,
- rheum (RF, ESR, ANA, APL, lupus, ANCA),
- hypercoag (fibrinogen, FVL, AT, pn20210 pm, pn C&S if young...)

IF ECG abnormal, order ECHO.

All normal, next?

Ideally diffusion weighted MRI of the head, if not available CT head

For TIA, MRI will pick up changes before CT

Then accredited lab US of carotids

- Why CT? to r/o
 - SOL
 - hemorrhage,
 - old strokes,

- lacunar strokes,
- check laterality
 - and likelihood of central embolic disease

CT - old stroke in R hemisphere... nil else. When do you want US?

Within 24 h by guidelines.

r/o other causes of stroke:

- FMD, kink, dissection, aneurysm, arteritis (GCS, Tak), hypoperfusion, hypercoag state, lacunar stroke
- r/o mimickers:
- migraine, SOL, metabolic (delirium, sepsis, hypoglycemia), vertigo, seizure

Aside:

If pt has carotid source and AF: most likely cause of stroke would still be AF...

only 10-20% of ischemic strokes are caused by carotid. The rest - AF, arch, intracranial.

Prognosis of TIA

- Stroke after TIA
 - Highest in the first 2 weeks
 - Overall 6% per year
 - 10% 1st year, 16% at 2nd year, 26% at 3rd year,
 - then declines...
 - Stratification of TIA risk:
 - if risk factors present:
 - A=>60 yo age, (1 point)
 - B=BP >140/90. (1 point)
 - Clinical=hemispheric (2) vs monocular (1),
 - D=duration, < 1 h (1), > 1 hour (2)
 - D=DM (1)
 - risk of recurrence may be as high as 8% in 2 days according to ABCD²...
 - Total scores ranged from 0 (lowest risk) to 7 (highest risk).
 - Stroke risk at 2 days, 7 days, and 90 days:
 - Scores 0-3: low risk – elective surgery
 - Scores 4-5: moderate risk – urgent surgery
 - Scores 6-7: high risk – emergent surgery

Guide to ABCD2 Total Score		Stroke risk after TIA at:		
Risk Group	(Score)	2-day	7-day	90-day
Low	0 - 3	1%	1.2%	3.1%
Moderate	4 - 5	4.1%	5.9%	9.8%
HIGH	6 - 7	8.1%	12%	18%

- Recurrent CVA after CVA:
 - 9% per year, steady... p. 1880

	1 st year CVA recurrence	Annual recurrence	Recurrence declines?	Post CEA annual recurrence?
CVA	10%	9%	No	2%
TIA	10%	6%	Yes	<1%
Asymptomatic	-	2-5%	-	0.3%

Moore's data: If ulcer is > 40 mm² and cavernous – then annual stroke may be as high as 7.5%, even when no significant stenosis is present... Controversial.

53. How to interpret results of carotid US:

- Washington criteria – based on ECST, NOT NASCET angiographic correlation
 - ECST – outlines hypothetical normal carotid bulb and measures stenosis with respect to this
 - NASCET – compare distal ICA to stenosis
 - May get negative stenosis figures
 - Compared to ECST, predicts less severe stenosis

Washington criteria:

- Remember that it OVERESTIMATES the stenosis (ECST, not NASCET criteria)
- Remember, that it gives ranges that do NOT apply for NASCET (70% stenosis
 - However, ACAS (diagnosed by 60% stenosis BY ANGIO in that study) may correspond to 80% stenosis criteria by US...

- Normal: no plaque, smooth walls, boundary layer separation in bulb
- < 15 % mild SB
- 16-49% marked SB, no systolic window
- 50-79% PSV >125, PDV <140 cm/sec, marked SB, ICA/CCA > 1.8
- 80-99% PSV >125, PDV > 140 cm/sec, poststenotic turbulence, ICA/CCA > 3.7
- Occlusion: no flow
 - May be wrong in 3% of cases – hence ALWAYS confirm this with angio or MRI.

Consensus panel on US criteria on stenosis:

- These are more practical than Washington – based on Nascet technique and range of measurements of stenosis:

- <50%
 - PSV <125
 - EDV <40
 - Ratio <2

- 50-69
 - PSV 125-230
 - Visualized plaque
 - EDV 40-100
 - Ratio 2-4

- >70
 - PSV > 230
 - Visible plaque

- EDV > 100
- Ratio >4

Aside notes on Abnormal velocities:

False elevation in ICA PSV :

- Contralateral occlusion
- Hyperdynamic state
- Bad angle
- Post stent or endarterectomy

PSV in carotid stent:

- >150 cm/sec is NOT >50% stenosis
- Psv>300 and EDV
- > 240 – predicts high grade stenosis but need angio to confirm

Carotid occlusion

- Waterhammer waveform (sharp up and below zero line downstroke, no diastolic flow)
- Acute thrombus
- No flow in ICA
- In imaging:
 - Use power Doppler
 - If pulsed:
 - Keep PFR low to detect low flows
 - Increase Doppler gain to ID slow velocity

Canadian Vascular Surgery In-Training Cases, U of Ottawa, Anton Sharapov, MD, 2008

Innominate stenosis:

- Decreased CCA wave
- Reversal of flow in ICA and CCA
 - Crouching bunny waveform
- Carotid steal can only happen on R side
 - See reduced PSV in ICA, reversal of flow in diastoli

Long severe stenosis in ICA will have reduced PSVs, not elevated...

- Hence always rely on ratio ICA/CCA in these cases.
- Make sure CCA is not elevated (i.e. >100 – due to c/l occlusion)

Other useful velocities measurement for carotids:

- >60% stenosis – ACAS stenosis range validated in Oregon with angio
 - PSV >260, EDV >70, ratio > 3.2.
 - Accuracy 90%
- NASCET > 70% stenosis
 - PSV >280, EDV > 80, Ratio >4
 - PPV 95%
- >80% stenosis
 - PSV >250, ratio >4
 - 90% accuracy for 70-99% range
- Intraop duplex assessment of CEA
 - Repair if PSV>200
- Subclavian artery stenosis

- Retrograde (notched) vertebral flow
- No graded PSVs values vs occlusion for vertebral artery flows

54. CEA: indications for symptomatic and asymptomatic pts

Two scenarios:

Scenario 1: Symptomatic 65 yom with hemispheric TIA (L sided weakness)

Duplex shows R > 80% and L <69%. No comments on plaque quality. Next?

No kinks/loops/proximal CCA irregularities? no

I can trust the Doppler. Will have a discussion: He needs TIA is an emergency situation...

Need to stabilize plaque, settle platelets

aggressive RF management - BP, aggrenox (had TIA on aspirin),

large dose of lipid agent

Jupiter trial results show reduction of CVA/MI in pts on statins. In asymptomatics with normal Lipids, no RF for ASC and elevated CRP.

Plus, he has symptomatic critical R carotid stenosis - likely source of his TIA. I recommend surgical approach. Needs surgery within 2 weeks.

What evidence? not sure he wants surgery...

Number Needed To Treat (NNT) for symptomatic:

- NASCET
- 2 year study
- Asa vs ASA/CEA
- Ratio of stenosis diameter to normal proximal ICA

- 26% vs 9% for 70-99%, ARR 17% overall....
 - NNT 6 for < 75 yoa
 - NNT 3 for pts > 75 yoa
 - **major/fatal stroke 13% vs 3% ARR 10%**
- 22% vs 16% for 50-69%, NNT 17
 - **No difference in major/fatal stroke**
- Need complication rate < 6%

TIA has risk of stroke about 6% per year,

if RF (hemispheric vs monocular, >60 yoa, >140/90. duration > 1 hour, DM - risk of recurrence may be as high as 8% in 2 days according to ABCD²...

NNT:

6 for >70% and <75 yoa,

3 for >70% and >75 yoa

17 for 50-69%

**Dr. H.J.M. Barnett: The appropriate use of carotid endarterectomy. JAMC, 2002
One of NASCET investigators...**

- **Symptomatic > 70% stenosis.**
 - All pts are better off with surgery, but...
 - Most benefit seen in:
 - Healthy elderly pts > 75 yoa
 - Hemispheric TIA (vs monocular)
 - Pts with tandem extracranial and intracranial lesions
 - Pts without angiographic evidence of collateral pathways
 - Perioperative risk is higher in the following pts, BUT surgery is still beneficial:
 - Widespread leukoaraiosis
 - Significant risk factor for stroke
 - Poorly defined hypodense white matter lesions
 - Unlike sharply defined infarcts
 - Overall benefit is smaller
 - Occlusion of CL carotid artery
 - Intraluminal thrombus
- **Symptomatic < 70% stenosis:**
 - For most benefit smaller. The following pts may be HARMED, particularly if they have few Risk factors :
 - Pts with monocular TIA
 - Women
- The presence of the following RF increase benefit:
 - >75 yoa
 - Male
 - IC

Caveats:

- CEA carries 2% incidence of Disabling stroke. So:
- Precise measurement of stenosis is essential

Canadian Vascular Surgery In-Training Cases, U of Ottawa, Anton Sharapov, MD, 2008

- Follow exclusion criteria:
- Impending organ failure
- Serious cardiac dysfunction
- Late stage cancer
- These pts not likely to benefit...

How about asymptomatic side?

- ACAS
- 39 centers, elite surgeons
- Good risk pts, mostly men
- 5 year results
- Most events occur after 3 years
 - Stat significance only after 5th year
- Stenosis > 60 %
 - **But NO dependence between extent of stenosis vs benefit**
 - 11% vs 5%, ARR 6%, NNT 17
 - men 12.1% vs 4.1% - ARR 8%
 - **women 8.7% vs 7.3% ARR 1.5% not stat significant**
- Fatal stroke and disabling stroke – no stat difference
- Need complication rate < 3%

- Females or > 80 yoa likely no benefit
- Study recommended surgery for good risk male pts with 3 year life expectancy, at least 60% stenosis. Results for women less certain.

ACST findings:

<http://stroke.ahajournals.org/cgi/content/full/strokeaha;35/10/2425>

- Larger study
- community surgeons, no elite requirements
- **the only study to show stat sig difference in fatal/disabling stroke of 2.5% in asymptomatics**
- females have TINY stat significant benefit, uncertain clinical benefit

So would I offer surgery on asymptomatic side?

- risk of stroke for asymptomatic < 80% is generally low
 - 1-2%/year,
 - 425 pt, stable 50-79% stenosis
 - 5 year cumulative risk of event is 5.4%

Canadian Vascular Surgery In-Training Cases, U of Ottawa, Anton Sharapov, MD, 2008

- Recommendation to consider OR above 80% stenosis only
NNT is 83 according to Barnett paper (1 % yearly, i suppose)
17 according to NEJM review (for 5% ARR over 5 years...).

- Risk of an event with stenosis above 80% - may be as high as 11% per year.....
the greater the stenosis, the more RF there is, the greater the incidence of stroke..
some report incidence of stroke in >80% as high as 35% at 6 months
also, only 30-50% of pts with CVA have an antecedent TIA
so can't rely on waiting for reversible symptoms of TIA as a warning system for incoming stroke...

- **Still, the most common event in ACTS/ACAS – MI, NOT stroke.**

ACAS acquired statistical significance for strokes only after a small burst of strokes after 5th year of follow up

i.e. no significance would have been reached if only followed for 4 years
only 1/3-1/2 of ischemic strokes were referable to ipsilateral carotid stenosis.

Unfortunately, the very same factors that make stroke more likely without an operation, also increase perioperative risk of stroke...

In ACAS, the following factors increased **perioperative stroke, TIA, or death**

- **Anatomical factors:**
 - Contralateral carotid stenosis >60%
 - Contralateral siphon stenosis
 - Clinical factors:
 - Prev CVA
 - Hypertension
 - DM
 - Female gender
 - Age >75 yoa
 - CHF
 - Procedural factors:
 - Combined carotid-cardiac surgery

i.e. CL disease, PVD factors, female, age >75

At the same time, the following factors increase risk of having a stroke in asymptomatic stenosis if followed non-operatively:

Anatomical factors:

- Soft, echolucent plaques

Canadian Vascular Surgery In-Training Cases, U of Ottawa, Anton Sharapov, MD, 2008

- CL ICA occlusion
- Silent ipsilateral infarction on CT
- Htn
- Dm
- Smoking
- Hyperlipidimia
- Hyperhomocystein

Clinical factors:

I.e. PVD risk factors...

- so the decision to do surgery in asymptomatics is not an easy one...
 - on the one hand, multiple RF make pts more prone to stroke (from baseline 2% to as high as 11%)
 - on the other, the very same RF make pt more prone to perioperative CVA/death.
- Also, the benefits of CEA do not get realized until 3rd year post op and it does not appear to be cost effective in 80 year olds, or females
- Medical therapy is getting better. Jupiter trial showed 50% reduction in strokes and MIs with statin therapy at 2 years in asymptomatic pts with normal lipids but elevated CRP.

Conclusion:

- If pt has
 - less than 3 year life expectancy,
 - CL occlusion/stenosis,
 - has FEW vascular RF,
 - is a female
 - under 80% stenosis,
- ... medical therapy is beneficial. Particularly statins (Jupiter trial).

Who is an ideal asymptomatic candidate for CEA?

- male
- < 75 yoa,
- >80% stenosis
- RF for PVD
- No contralateral occlusion

If decision to operate is made, it is imperative for the operator to have less than 3% combined M&M stroke risk to ensure gradual realization of 6% (at most if male) of absolute risk reduction over the next several years...

So for the exam intent, unless you can prove to the examiner your record of asymptomatic CEA is low and you understand the risk variation with different RF thrown in the mix, I'd be careful suggesting CEA for an asymptomatic pt....

Carotid Stent - still investigational. Crest –for symptomatic pts is not out yet... Reserved for high risk Symptomatic pts (technically or physiologically). For asymptomatic – use stent in off lable investigational setting only

What is High risk pt? p. 2010

- Severe CAD requiring PCI or CABG
- Hx of CHF
- Severe COPD requiring home O2 and FEV₁<20% predicted
- Severe renal failure (Cr > 3 or 240 or on dialysis)

- Prior CEA with restenosis
- Surgically inaccessible lesion – at/above C2, inferior to clavicle
- Radiation induced stenosis
- Prior ipsilateral radical neck dissection
- CL vocal cord paralysis
- Tracheostomy
- Neck fusion

Scenario 2:

Male, 65 yoa, symptomatic side is 50-69%... Surgery?

- Will discuss re:
- risk benefit – NNT is 15,
- no statistically sig reduction in major or fatal stroke...
- I'd recommend surgery for symptomatic side provided pt understands risk benefit ratio.
- i.e. pt has to be male, has RF for PVD, TIA is hemispheric.

Preop discussion?

M&M about 6%, complications:

IMMEDIATE:

- neuro - periop stroke/hyperperfusion,
- local - bleed/infection/Cranial n (hypoglossal, marginal) – most are reversible ,
- systemic - HD instability/MI.

DISTANT:

- restenosis - 10% at 2 y, 17% at 10 y – intimal hyperplasia vs Atherosclerosis... patch reduces incidence of restenosis.

Canadian Vascular Surgery In-Training Cases, U of Ottawa, Anton Sharapov, MD, 2008

- Aneurismal degeneration of patch

Ok, goes to surgery. How do you do this? Awake, regional anesthesia.
Or asleep, with monitoring (EEG, evoked potentials) or routine shunting.

Local anesthetic, beach chair, supplement local, selective shunting, patch.

Why selective shunting?

- will use live neuro assessment to assess 3 min clamp effect.

What shunt?

- pruit-inohara - has side port
- Alternative – Argyle – a simple tube with Rumel tourniquet distally and clamp proximally.
 - It has no side arm – so can't check if it is working properly...

55. Conduct of CEA:

- Consent: indications, risk and benefit discussion
- Beach chair position, neck extended, head turned
- Regional anesthetic, monitor CL arm activity and frequent neuro checks
- Ear-lobe – to nipple prep
- Cut along ant border of SCM
 - Skin
 - Platysma
 - Reflect SCM laterally
- Go in front of jugular vein, ID & ligate facial vein
 - Key to bifurcation
- Enter sheath, preserve ansa and vagus
- Dissect “patient away from artery”
- Loop CCA, ECA, sup thyroid, ICA
 - Preserve hypoglossal
- Inject bifurcation with lidocain, don't dissect there
- Ask neuro to maintain BP, neuro check, heparin, circulation time
- Test clamp ICA with baker clamp, neuro check
- Clamp CCA, ECA, clip sup thyroid
- CCA-bulb-prox ICA longitudinal arteriotomy
- Penfield or Dallar tool plus Right angle
- Transect plaque in CCA, work it up around ECA orifice, transect at the base of the ICA
- Eversion ECA endarterectomy
- Continue EA plane to ICA, feather out or tack with 7:0

- Clean surface
- Patch and flush
- Unclamp ICA – then reclamp
- Unclamp ECA and CCA
- Finally unclamp ICA, neuro check
- Protamine, hemostasis
- Close platysma

Say artery is kinked –
i'll bemoan inaccuracy of US as i would have liked CTA or MRA or angio.

What to do?
shorten ICA and do patch closure with dacron. Will I patch in all cases? For ICA - yes.

Advantages of patching:
Decrease carotid thrombosis
Decrease periop neuro event
Decrease restenosis rate

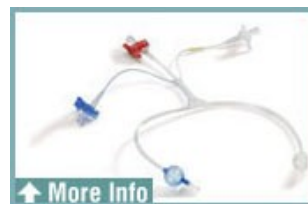**Based on Cochrane review, 40 events prevented per 1000 pts operated upon.
No reduction in fatal stroke or all death.**

Shunt placement:

Pruitt-Inohara: by Lamaitre.

- Outlying and inline version.
- ICA limb is smaller than outside port – allows debris to go preferentially to outside port, not ICA.
- ICA limb has security balloon that prevents overinflation.
- CCA end is blue – 14 mm, 1.5 cc, ICA end is 8 mm max, 0.25 cc.

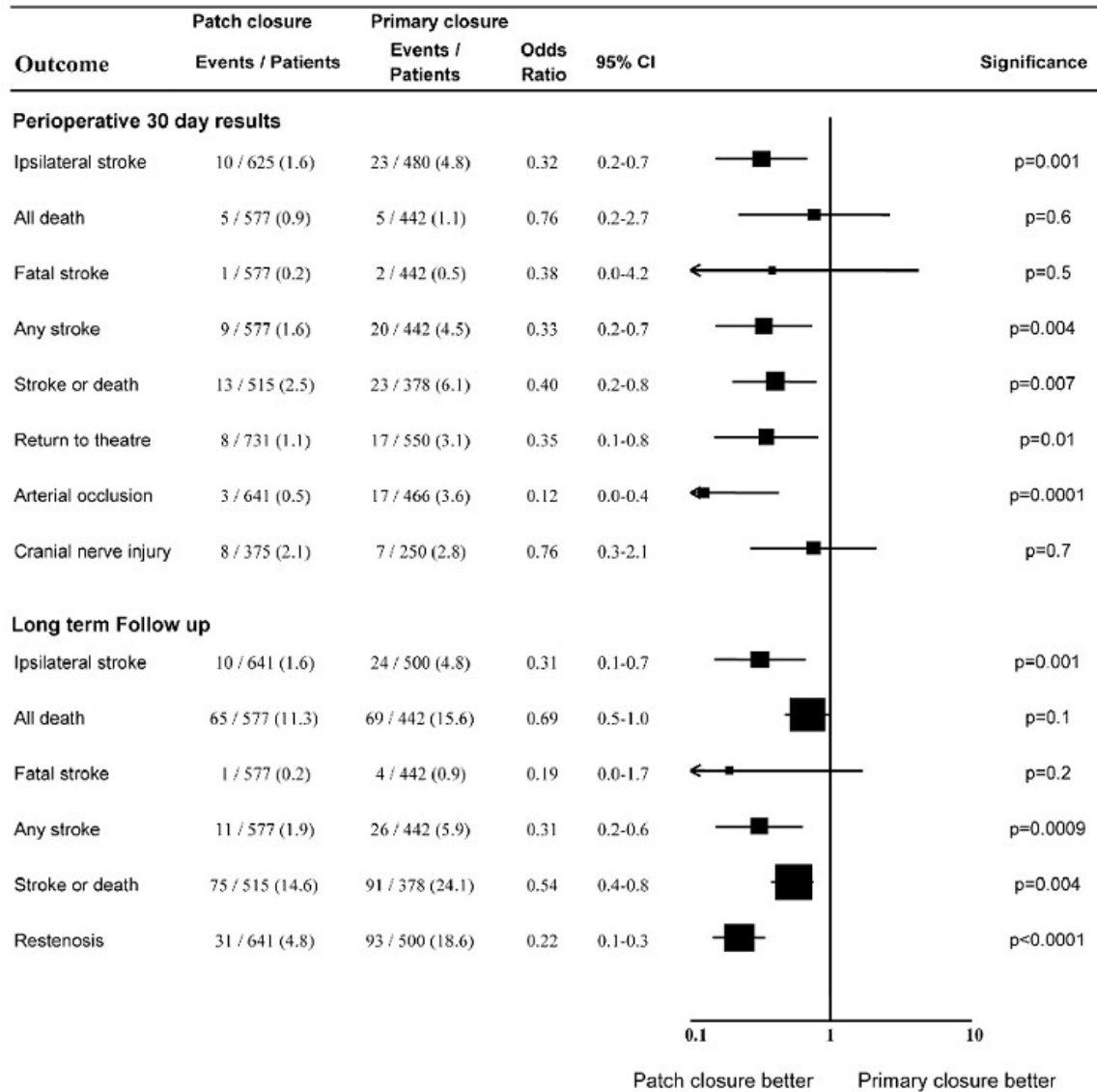
- Balloons allow to stent open the artery.
- 9 Fr system, allows 180 cc/min for outlying shunt.
 - Need about 140 cc/min



- Clamp ICA/CCA/ECA, arteriotomy, may remove gross plaque first or proceed with shunt
- Shunt comes in with occluder balloon if choose remove plaque first. May dispense with this step
- Place ICA balloon in first, slide security sleeve off, back bleed, inflate balloon, replace sleeve on.
- Back bleed ICA limb through port, clamp ICA limb.
- Place CCA balloon in, remove CCA clamp – expect some bleeding, inflate balloon.
- Back bleed CCA limb through port
- Unclamp ICA and CCA – back bleed both through port, close port. Shunt is working.

Canadian Vascular Surgery In-Training Cases, U of Ottawa, Anton Sharapov, MD, 2008

- When putting a patch, start sewing distal to proximal, once gone past bifurcation, may clamp CCA below bifurcation and remove shunt. ECA will perfuse ICA now.
- Complete patch, finger collapse ICA, open ECA and CCA, flush to ECA, open ICA.



For Javid shunt: straight tube, soft ends, outlying version.

- place ICA end in first, snug with Rumel tourniquet, back bleed,
- place CCA end in, fill up CCA stump with blood distal to CCA clamp
- Place shunt clamp, release CCA clamp, flush the stump, tighten up Rumels,
- Release shunt clamp, watch for bubbles in the tube. Shunt is working.

Disadvantages of shunts:

- Longer clamp time
- Potential for blowout (if vein)
- Potential for infection (if Dacron)

Shunt complications?

- Dissection
- Embolization
- Migration
- Blockage by debris
- malfunction

56. Post CEA neurological deficit:

1.5 h post OR L sided weakness and HA, you are scrubbed. Next?

- I'll delegate anesthesia to assess his BP - normal - or ask colleague to replace me to assess pt myself.
- Will ask for duplex if available

Key questions to answer:

1. **Is pt lucid upon awakening or has a neuro deficit?**
2. **Did neurologic deficit resolve completely?**
 - **i.e. was it a TIA?**

Once these questions are answered, check if the artery paten and see if there are technical problems at anastomosis.

In general, **if pt woke up with neurological deficit, the most likely problem is that of perioperative hypotension, with watershed infarct.** If this is the case, establishing the need for re-clamping the artery is very important: if the artery is open, and there are no technical problems on duplex, then you don't need to HYPOperfuse already stressed brain. You need to scan the head to see 1) CVA and 2) clot/debris (less likely).

If reliable duplex is not available, go to OR for Doppler exam after you opened the wound.

If there is flow, on table angio prior to opening up the patch is important:
would save the penumbra a second hit of unneeded clamp time.

If there is technical problem/clot – then one needs to repair these. Time line for this is fairly short, i.e. max 3 hours...

A period of lucency accompanied by onset of neuro deficit in the setting of HTN, seizures is suggestive of hyper-perfusion syndrome. Keep BP between 100-160 mm Hg. Control BP, ICU, scan to look for bleed (diffusion weighted MRI to DD edema vs bleed for prognostic purpose. Hyperperfusion happens on 2-3 day. May want to avoid antiplatelet and anticoagulation if diagnosed hyperperfusion. Use transcranial Doppler for confirmation.

Scenario 1: Neurologically affected post op patient. Duplex available and is normal (B mode and velocities).

I'll do emergent CT (no contrast first) then CTA looking for distal embolism and operative site

- See nothing on CT.
 - I will attribute symptoms to watershed hyperperfusion ischemia
 - less likely, micro atheroembolism.
 - Supportive care, BP control (not too high, not too low)
- Suppose see clot/debrue in MCA...
 - Ask neurorads to assess – tpa vs experimental merci retriever...
- Suppose see occluded ICA repair:
 - If pt is totally neurologically recovered by the time you completed you duplex and CT, (i.e. this was a TIA), then I'll just anticoagulate and cut my losses.
 - May be dangerous to explore here.
 - If pt is not neurologically intact, then I'll need to open up the artery (see below)

Scenario 2: Neurologically affected post op patient. No duplex available.

- will take to OR,
- prepare for general AND shunting
 - protective metabolic effect on brain, control airway, procedure may take time

- flow is present on Doppler in OR –
- do angio 1st through patch. If problems seen -
- incise patch, if back flow
 - place shunt,
 - examine for intimal flaps, defects.
 - **Failure to repair these defects with flow still present in the artery will result in continuous embolisation with intimal flap being a nidus.**

- if graft is completely thrombosed on Doppler:
 - **no distal clamp at first**, incise patch, milk out clot, use #2 fogarty to the base of the skull.
 - if go into cavernous sinus – high risk of carotid cavernous fistula – big swollen reg eye. Needs stent assisted emolisation. Dangerous, may lose sight...

- Get blood -> shunt -> and angio (C arm) via shunt side arm.
- If I see clot in distal ICA in skull - ask for neurorad colleague to assist with clot retrieval vs TPA (1 mg) but that's controversial...
- if repair occluded without any sign of technical problem, then the problem here is hypercoagulable state here
 - antiplatelet meds need to be considered.
 - Alternatively, replacing raw clot-stimulating carotid with an interposition graft is appropriate as well.

Scenario 3: Pt had TIA in recovery but currently is neurologically NORMAL.

Regardless of what duplex or CT is going to show, nothing needs to be done SURGICALLY for this pt apart from usual periop care.

- Worst case scenario: If graft is thrombosed but pt has normal neurological status
 - it is safer to anticoagulate without repair
 - Thank your lucky stars
 - Risk of trying to extract clot (up to the level of ophthalmic artery) may be excessive: may need to do tPA etc...
 - 4 out 5 established surgeons I asked would choose to wait but one decided to take to OR if within 3 hours...

What type of clot seen? white clot.

Management after CEA?

- put on plavix or aggrenox, neuro to see, manage RF, repeat US and see if previously seen <69% stenosis is downgraded.
- Duplex - my practice on discharge, at 3, 6, 12, 18, and then yearly for both operated and CL side
 - Note, some recommend one time US at either 3, 6, or 12 months...
 - Then f/u for Contralateral side only...

57. Intraoperative thrombosis during CEA:

- Review specifics of pt
 - Demographics,
 - Indications for surgery,
 - Preop hx of hypercoagulable state
 - Peri-operative details
 - BP management
 - Heparin details and ACT values
 - Previous reactions to heparin or exposures to heparin
 - Symptomatic (if done under regional)

- Type of clot forming – white vs red
 - Where and at what time of the procedure is clot forming
 - On endarterectomized surface
 - In operative field
 - Prox/distal carotid
- DD:
 - Hypercoagulable state
 - Reaction to heparin
 - Inadequate heparin
- Check for ACT –
 - If ACT is low despite recent heparin administration suspect HIT
 - stop heparin, send for stat HIT screen
 - ask for hematology consult and for direct thrombin inhibitors
 - argatroban, lepirudin
 - if ACT is high and appropriate with recent heparin dose, suspect hypercoagulable local state (endarterectomized surface)
 - may need to do interposition vein graft

58. Hyperperfusion syndrome:

- 2-4 day, Headache and seizures
- CT – do NON contrast first to r/o SAH bleed, stroke
- Confirm by transcranial duplex
- Seen in 0.04-1.2% of CEA
- Chronically hypoperfused arteries may lose an ability to autoregulate flow
- Control blood pressure
- Avoid antiplatelets and anticoagulation
- In extreme cases, may need to decompress skull

59. 80 yof, 80% asymptomatic carotid stenosis.

- How do you manage the pt. (H/PE/indications).
 - Assess life expectancy
 - RF
 - Jupiter trial results
 - Suggest conservative management
- Agree for OR only after COMPLETE understanding of risks and benefit is reached...
- Describe CEA.
- Shunts/patches/risks/postop neuro deficit.

60. Pt had TIA, history and exam is negative, Duplex, CT- head normal.

- DD of TIA

- Partial complex seizures
- Complex migraine
- Demyelinating process
- Conversion disorder
- Dissection
- Embolism, dvt and PFO
- Moyamoya disease, CTD, hypercoag
- Should have had MRI head to r/o subtle post TIA changes but won't tell you what the source is..
- Likely embolic event, need to image arch, carotids with CTA
 - arch, proximal and distal carotid disease (kinks, FMD, dissection, aneurysm)
- CTA – shows ICA aneurysm at C 1-2 level. Next?

Balloon occlusion test with DSA.

Aside:

Types of carotid aneurysm...

- True aneurysm:
 - Atherosclerotic
 - Degenerative
 - Congenital
 - Traumatic

Fusiform > saccular, frequently bilateral (20%)

- False:
 - Mycotic
 - Used to be most commonly due to peritonsillar abscess
 - Post patching
 - Penetrating trauma

Complications:

- Embolization (most frequent)
 - 66% TIA, 8% stroke.
- Thrombosis
- Rupture
- Dissection

Indication for repair:

- >2 cm or symptoms

- Untreated disease – 21-50% stroke rate

Treatment options:

- Location
- Size
- Shape (saccular – may be able to embolize, fusiform – stent across)
- Comorbidities

Options include:

- ICA ligation
- Resection and anastomosis
- Resection and interposition graft
- Extracranial – intracranial bypass
- CAS

Open surgical approaches have combined morbidity/mortality/stroke rates of 11% and CN injury 20% in best hands...

Maneuvers to improve exposure of high ICA: difficult ICA

- Standard access – upper half of C2
- 1st maneuver - lift hypoglossal up
 - Cut branch of occipital or sternocleidomastoid artery –
- Divide posterior digastrics m – gets you to middle third of C1
 - Extend incision to mastoid
 - Mobilize and elevate lower pole of parotid gland
 - Transect SCM at mastoid process
- Subluxate TMJ (call for head and neck surgeon to help)
 - Note – do not DISLOCATE – will compress CL carotid
- Resect styloid process – upper half of C1 in 50% of cases
- Cut off posterior portion of the mandible ramus – above C1 in 100% of cases
 - Lateral mandibulectomy
 - preserve inf. Alveolar nerve
- Finally, going retrojugular on initial approach exposing the carotid can get you surprisingly high... (Dr. Hajjar/Lewis)

61.55 yom smoker, TIA, 50-79% on duplex

Review velocities and use consensus statements, not Washington.

Indications for angio for carotid:

Canadian Vascular Surgery In-Training Cases, U of Ottawa, Anton Sharapov, MD, 2008

- In equivocal duplex findings
- Duplex can't show extent of disease
- Suspicion of tandem lesion
 - Arch or intracranial
- Uncommon carotid pathology
- Trauma
- Work up for stent

I.e. Can't trust duplex (kink, aneurysm, proximal CCA irregularity) or need a stent

Agio showed 95% stenosis and acute thrombus in ICA

- Describe in detail technique of CEA
- Defend your choice of shunt/patching technique
- Defend CEA vs CAS
- Monitoring available:
 - Awake and clamp trial
 - EEG
 - Stump pressure
- Describe technique of eversion EA of ICA
- One hour post op, CEA pt has neurologic deficit. Manage.
- Open carotid – and ICA is thrombosed. Manage.
 - Gentle #2 Fogarty up to the skull base (risk of carotid-cavernous injury/fistula).
- How do you infuse tPA in carotid.
 - With fear and trembling
 - First, review contraindications
 - Some say 1 mg and back off, some say up to 5
 - I'd say call neurorads...

62. 76 yom, asymptomatic bruit on L. Class 3 angina, ESRD on peritoneal dialysis.

- What investigations?
- Interpret Duplex – Washington criteria and Consensus.
- Say it is 50-69%. Next?
 - RF modification, aggressive, follow DUS
- Comes back with a TIAs. Has residual left sided weakness. Next?
 - Asked for repeat duplex or CTA.
 - Occluded Left ICA. Right ICA moderate stenosis. Arch OK, verts OK.
- Next?

- consider this patient a high risk patient because of his cardiac history and ESRD
- he is symptomatic with a contralateral occlusion
- if he failed conservative therapy, has acceptable longevity he should be repaired
- consider CAS

63. A young lady presented with a mass in her neck.

DD: very brief pathetic list here... but will suffice for vasc board..

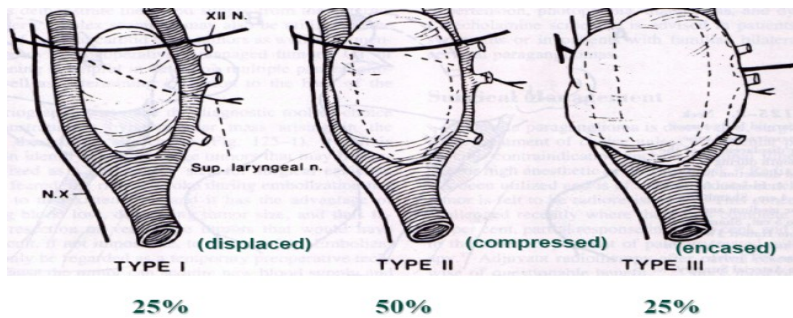
- Lymph node:
 - Lymphoma
 - Met tumor
- Salivatory tumor
- Thyroid mass
 - Tumor
 - Overgrown gland
- Branchial cleft cyst
- Vascular:
 - Carotid aneurysm
 - Carotid kink
 - Carotid body tumor

- initial investigations
- DUS suggestive of a carotid body tumor. Further investigations?
- describe the typical findings on angiography.
 - Splaying of the bifurcation
 - Blood supply from EIA
 - Well vascularized
- appropriate management of these lesions
- details of the surgical procedure
- specifically the risks associated with the procedure

- Carotid body arises from afferent ganglion of Glossopharyngeal n.
- Paraganglioma, chemoductoma
- Chemoreceptor responsive to hypoxia, hypercarpnia, acidosis
 - if stimulated will increase RR, tidal volume, HR, BP, vasoconstriction, catecholamine release
- Neural crest ectoderm and mesoderm that migrated along the afferent nerves
- Autosomal dominant inheritance, but most sporadic
- 5% rule:
 - Metastatic
 - Biochemically active – pheo...
 - Bilateral (30% of these are familial)

a. May be part of MEN 1 and 2

- Differentiate from hyperplasia in high altitude dwellers
- On exam –
 - pulsatile, not expansile,
 - can move it sideways but no up and down
- Sensitive to rads but the only definitive control is surgery
Shamblin classification:



What is the carotid body afferent input to the reticular formation in the medulla?

- Via glossopharyngeal n.
- Connects CB to brain stem so that it can respond to hypoxia (primarily), and (lesser degree) hypercarbia/acidosis
- Stimulation produces increased RR, BP, vasoconstriction

64.Head and neck colleague asks for help in OR. 20 yof with neck mass:

In OR for bx near carotid bifurcation, keeps bleeding.

Frozen section: tangle of capillaries

- You expose vessels, bleeding stops with direct pressure, see 2 cm mass.
- What next? No family around to get consent.
- You close and wake pt up.

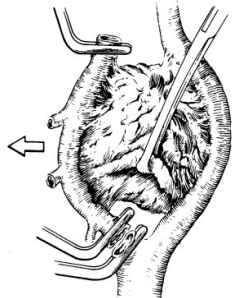
Work up:

- Duplex
- CT/MRI (location, surrounding structures)
- How do you screen the other side?
- What's association with MEN
- What does literature say about embolization?

- How do you resect the tumor?

Notes:

- Angio to ID blood supply and carotid anatomy
- Classify Carotid body:
- Shamblin:
 - Group 1 – easy to resect, no in growth in the carotids/nerve
 - Group 2 – moderate ingrowth, may require shunt
 - Group 3 – heavy ingrowth, need to expose distal ICA and resect artery
- Catecholamine screening
- Check CT for bilateral tumors
- Preop CN check
- Help from Head and neck surgeon
- Preop discussion –
 - 20-40% risk of CN injury!
- **Nasal intubation in case of need for subluxation of mandible**, prep groin for GSV harvest
- prepare to shunt
- Bipolar cautery, cell-saver
- Standard exposure
- Dissect in direction from caudal to cephalad
- Peri-adventitial plane,
 - if can't develop it – may have tumor ingrowth, consider resecting carotid
- Points of difficulty – bifurcation and posterior (adherent RLN)
- May have to mobilize parotid gland to expose distal ICA
- Alternatively
 - may divide post belly of digastrics muscle and styloid lig to get distal ICA
- Get proximal and distal control, including ECA
 - May transect ECA proximally
 - helps with bleeding control and can use that as a handle
 - No need to reconstruct ECA afterwards, just oversew the stump



Copyright ©2005, 2000, 1995, 1989, 1976 by Elsevier, Inc.

- ID hypoglossal and vagus

65.70 yof, asymptomatic 70% ICA stenosis and carotid tumor on follow-up.

- Approach.
- Fix both lesions while you are there
 - Preoperative w/u. operative steps. (need to do DSA)
 - Post op complications?

66.50 yof, L hemispheric TIA, 90 % L CCA stenosis at the aortic arch.

Also, 90% innominate artery stenosis at the arch.

Not vasculitic in appearance. L subclavian artery is normal.

Approach:

- Elicit sx of arterial insufficiency to the brain, UE, on both sides
 - If no symptoms – DO not repair
- Risk stratification re: cardiac/pulmonary/renal, RF management
- CT scan head/arch angio
- How do you repair this?
- Do you need to repair even if he is asymptomatic?
 - **Some say Yes, lesion is preocclusive**
 - I spoke with others – senior former board examiner told me to leave it alone...
 - median sternotomy and supra-aortic trunk reconstruction if good risk pt, otherwise extrathoracic repair.
- If pt is clearly unfit for median sternotomy, how would you reconstruct the symptomatic (L) side?
 - carotid subclavian bypass/transposition
 - retrograde PTA and stent from L carotid (controlling L carotid)
 - good option if subclavian is occluded.
 - Open alternative – xover bypass from the other carotid

67. Occluded CCA with symptomatic (amaurosis fugax) ECA stenosis on angio.

Among pts undergoing cerebral angiography, 4-5% have occluded CCA. Most of the time, ICA and ECA are also occluded. Matters are complicated if ICA and ECA are open.

Riles classification of occlusion CCA and its' branches

- 1A CCA occluded, ECA & ICA open
- 1B CCA and ICA occluded, ECA open
- 1C CCA and ECA occluded, ICA open

2 all three occluded

If patient is symptomatic, then repair is indicated and several small studies showed good results in relieving symptoms of global hypoperfusion and vertebrobasilar insufficiency.

Generally, for 1A and 1C, if patient is asymptomatic prognosis is uncertain: Some surgeons believe that surgical intervention is unwarranted, some believe the opposite. Natural history is unknown.

Some (Kniemeyer et al) suggest that even despite anticipated 15.4% risk of TIA and stroke with surgical management, all asymptomatic CCA occlusion with patent ICA should be revascularized to prevent progression to ICA occlusion and stroke. Others (Martin et al), believe that these pts can be followed with no risk of stroke: all their pts after 3 years of follow up were stroke free. Cull et al (An Vasc Surg 1999, 13:73-36) believe that asymptomatics have benign course and should be observed...

68. Angio on pt with TIA: ICA is occluded but CCA and ECA are open, ECA stenosis.

Indications for external carotid endarterectomy

- Occlusion of ICA AND symptoms attributable to ipsilateral ECA stenosis.

69. Combinations of carotid and coronary disease and approaches to both.

CEA and CABG – decision making in vasc surgery: p. 86

- Risk of stroke for CABG alone is 6.7% in Hertzner RCT
- Define high vs low neuro risk
 - High – these need to be addressed either before or during CABG
 - bilateral severe (>80%) asymptomatic
 - unilateral severe symptomatic
 - unilateral severe asymptomatic with CL occlusion
 - Low risk – unilateral severe asymptomatic: this can wait and followed on duplex
- Define High vs low Cardiac risk
 - Unstable angina HIGH risk
 - Stable angina LOW risk
- Pts which is High neuro and High Cardiac risk:
 - Controversial now that CAS and PCI are available
 - Traditionally Combined open:
 - Accept high risk of M&M for combined approach:

- 15- 17%
 - Unproven but logical Alternatives:
 - Local CEA then 48h CABG
 - PCI and CEA/CAS combined/staged
 - No good data to support one or the other
- Pts with High neuro and Low cardiac:
 - CEA first, then CABG in 4-6 weeks
 - Recent review (aug 2008 by Claggett) showed that CAS was worse than CEA for symptomatic, but better than CEA for asymptomatic combinations with CABG)
- Low neuro and High cardiac:
 - Cardiac first, then monitor carotid
 - Combined risk of complications should be less than 8%
 - If can assure this, may do combined, otherwise stage
- Low neuro and Low cardiac risk:
 - May do either, depending on the institution results – combined vs staged

70.Describe horner's syndrome in carotid dissection

- Sympathetic fibers running on top of the ICA are affected
- See:
 - Upper ptosis (Muller's muscle denervation)
 - Lower upside ptosis
 - Myosis
 - +/- anhidrosis and loss of ciliospinal reflex (neck pain – skin prick - causes ipsilateral pupil dilation)
- Note, in carotid dissection horner is incomplete, facial sweating is unaffected...

71.Causes of spontaneous carotid dissection

- Blunt Trauma
- FMD
- Marfan
- Ehlers-Danlos
- From type A or retrograded type B aortic dissection (Debakey 3C)

72. Describe dynamics of a steal phenomenon (vertebral a. steal)

For vertebral steal, one needs to have:

- Dominant vertebral a. affected (50% R, 25% both or L)
- Proximal subclavian (or innominate on the R) stenosis
 - Decreased peripheral resistance in upper extremity (due to exercise)
 - causes reversal of flow in vertebral artery
 - If artery is dominant, significant vertebro-basilar insufficiency is seen – symptomatic.

Carotid steal is only possible on the R: innominate stenosis causes reversal of blood flow in R carotid artery with R arm exercise.

To diagnose vertebral a. steal:

- Duplex
- will have same direction in CCA and subclavian (red), but reversed in vertebral (blue)
- important to have both clinical and duplex signs
 - some asymptomatics have duplex signs only, ignore these pts...

To treat steal is to treat proximal stenosis – subclavian or innominate.

- Endo
 - PTA, dodgy as may occlude/dissect vertebral/LIMA/RIMA origin
- Open:
 - Transthoracic
 - Thrombo-endarterectomy
 - Ascending Aorta innominate/subclavian bypass
 - Extrathoracic:
 - For R sided disease, ensure that innominate is open
 - Otherwise, will need crossover bypass
 - Carotid subclavian transposition
 - Carotid subclavian bypass
 - Axillo-axillary BP (rare, despised by purists)
 - Femor->axillary BP (rare)

Conduct of carotid–subclavian bypass.

- Preop discussion of Risks and benefits
- Duplex carotid in preparation to clamping
- Supine, GA
- Interscapular roll, head turned away
- Supraclavicular incision
- Platysma, fat pad laterally, preserve phrenic

- Transect scalene muscles
- Expose subclavian a.
- Reflect SCM medially, open up carotid sheath
- anticoagulate
- Measure carotid stump pressure with proximal clamp,
- if >50 mm Hg safe to forego shunt
- 8 mm Dacron or 6 mm PTFE
- EtSide carotid 1st then subclavian
- Transposition
 - Better than bypass
 - Single anastomosis
 - Autogenous, better patency compared to transposition
 - Supraclavicular incision
 - Transect SCM
 - Expose vertebral
 - Ligate thyroid branch of thyrocervical trunk and vertebral vein
 - Need to go PROXIMAL to vertebral and internal mammary
- Management of post op lymph leak from thoracic duct injury
 - If detected early post op – prompt exploration and ligation of thoracic duct
 - If detected late:
 - drain, NPO, TPN and short chain fatty acids
 - After 6/52 trial, may need to either explore the wound or consider R thoracoscopic procedure (clipping of the thoracic duct)

PELVIC AND INFRAINGUINAL STUFF

73. Advantages and disadvantages of insitu vs reversed vein bypass

No studies demonstrated superiority in patency for either in situ or reversed vein. In reality, in situ bypass – particularly in infrageniculate location - is partially tunneled and is ex-situ (non-reversed) to allow for more anatomically congruent orientation to the target vessel.

In situ advantages:

1. good size match between the vein graft and proximal inflow/distal target vessel
2. peri-adventitial vascular supply to the graft is preserved (theoretical)
3. if no side branches and perforators are seen on angiogram, skin incisions are avoided

In situ disadvantage:

1. technically more demanding, time consuming, requiring greater learning curve
2. trauma to the vein:
 - i. need to mechanically disrupt valves with subsequent intimal damage
 - ii. can't use on small diameter vein – will tear it with Lamette valvulotome
3. to definitively identify side branches need to do graftogram or Doppler

Reversed advantage:

1. no need for graftogram prior to harvesting
2. no injury to the valves and intima
3. ability to tunnel fully mobilized vein in the more advantageous course in the anatomic plane
4. convenient graft for short bypass that needs to be tunneled in a deep anatomic plane.

Reversed disadvantage:

1. poor size match between the vein graft and proximal inflow/distal target vessel
2. peri-adventitial vascular supply to the graft is disrupted (theoretical)
3. more extensive skin incision require to harvest (may be offset with laparoscopic harvesting)

74. Describe different types of ulcers:

- Leg ulcers
 - Classify: arterial, venous, mixed, other.
 - Appearance, location, associated stigmata, response to debridement, pain, response to elevation/dependency

Differential diagnosis:

- pyoderma gangrenosum,
- hypertension ulcers,
- calciphylaxis
 - small vessel calcification in RF pts on dialysis, calcium met problem, vit D overdose
- W&W infections:
 - underlying osteomyelitis, fungal, syphilis
- small vessel vasculitis
 - ANCA negative:
 - CTD, Buerger, essential cryoglobulinemia,

- ANCA positive:
 - Microscopic polyangiitis,
 - Wegener's
- Cancer
 - Marjolin ulcer (SSC), BSC, melanoma
- **Arterial ulcers** – painful, distal foot, shallow, punched out, non-bleeding, PVD skin signs (pale, shiny, thick nails, no hair, burger sign, vein troughing, arterial reconstruction scars)
 - Treat:
 - manage RF and control progression of IC
 - htn, hyperlipidemia, hyperglycemia, smoking control
 - muscle metabolism optimization-
 - walk therapy, pletol
 - Assess extent and location.
 - Assess longevity and functional level of activity
 - Surgery vs conservative.
 - Surgery:
 - ENDO
 - Bypass
- **primary amputation** – indications:
- consider in pts with CLI in the following pt subgroups:
 - non ambulatory
 - revascularization potential is irrelevant here unless pt has ischemic threatened stump for transfer/ambulation
 - extensive soft and bony tissue destruction
 - large area in young & good rehab potential
 - diabetic (neuropathic)
 - heal/plantar surface
 - mangled denervated extremity
 - life threatening infection

Conservative –

- local wound care –
 - improve oxygen delivery
 - CHF tx, edema, anemia, hypoxemia, hyperbaric
 - treat infection
 - local – antimicrobials,
 - systemic – antibiotics.

Don't use antibiotics for wounds that are not cellulitic but have necrosis/contamination/resident flora – resistance, additives cause irritation – use antimicrobials. Antibiotics are only for cellulitis and soft tissue.

- r/o W&W bugs, OM, cancer, venous component,
- assess nutrition, drugs
 - antimetabolites, chemo, immunosuppression,
- treat hyperglycemia.
- Stalled wound:
 - Promogran and regranex , plt spin off –
 - for growth factors to kick start granulation,
 - moist non-occlusive environment.
 - debride necrosis
- sympathectomy:
 - better for rest pain, may heal superficial ulcer
 - won't prevent amputation

Venous ulcer–

nonpainful, gaiter area (foot, gaiter, calf), signs of venous insuf – varicose, edema, brawny discoloration, atrophy blanche (healed scars and depressed fibrosed skin plus neovascularisation microvessels), lipodermatosclerosis – woody skin fibrosis. Bleed on exploration, better with elevation, not as painful.

- Hx:
- Epidemiology – gender, age, circumstances (trauma, occupation, inpatient)
- Sxs – swelling/ulcer/varicose/edema/duration/location/venous claudication
- Previous treatment, compliance & response
- Pmh – preg/dvt/surgery/hypercoag/
- Mimickers - CTD&RA, obesity, lymphedema, PAD, CHF, DM
- Fam hx – dvt, varix, coag

Treat:

- Conservative: compression and wound care.
 - Compression – stockings. CI – PAD – ABI < 0.8 (if 0.6 may still use light profor).
 - Profor – three layer – given for 3-7 days.
 - Aim – reduce ambulatory hypertension through superficial reflux elimination and skin vessel hypertension.
 - Local wound care –
 - debride, appligraft/skin graft, treat infection, r/o PAD and wound growth inhibiting factors.
- Surgery:

- Indications:
 - Ulcer
 - Pain
 - Bleeding
 - Cosmesis
 - SFJ thrombosis
- Reflux –
 - Superficial – GSV ligation and stripping
- Perforators – thigh – GSV ligation and stripping, calf – modified Linton+skin graft vs SEPS
- Deep – valve repair (banding, valvuloplasty internal/external), valve transplantation, valve transposition.
 - Aim – reduce/interrupt column of blood in thigh (sup and deep) and popliteal segment.
 - Does not work well in postthrombotic limbs.
- Obstruction – bypass & AVF, recanalization (endo)
- Other/experimental
 - Intermittent compression, pentoxifylin, iloprost, apligraf
- Contribution of superficial component to ulcer –
 - widely varies - 30-60%
 - Distal venous incompetence is very important.
- Plan – treat GSV reflux first, the other component may get better on its' own.

Rutherford – p. 113

- Venous valvular incompetence –
 - Distal only 23%
 - Proximal only 14%
 - Both – 45%
 - None – 7%
 - Ulcers – Bemmelen study - 76% had both above and below knee incompetence

Non healing venous ulcer:

- r/o tx non-compliance – 100% recurrence for non-compliant, 30% if pt is compliant
- revise diagnosis – PAD/Venous/neuro/vasculitis/htn/CTD-RA,PD/cancer/calculifalixis
- r/o infection (deep – osteo, superficial (fungal, w&w)
- kick start fibroblasts (debride, growth factors)
- improve oxygenation (treat hypoperfusion, consider bypass, hyperbaric)

Canadian Vascular Surgery In-Training Cases, U of Ottawa, Anton Sharapov, MD, 2008

- improve nutrition
- consider drugs that interfere with healing
 - steroids, antimetabolites, chemo, immunosuppressants

Neuropathic ulcers-

- Charcot arthropathy
 - **Due to neuropathy**
 - progressive condition of the musculoskeletal system
 - joint dislocations, pathologic fractures, and debilitating deformities
 - progressive destruction of bone and soft tissues at weight-bearing joints
 - can occur at any joint
 - MC at the foot and ankle.
- Autonomic dysregulation (dry nonsweating skin), intrinsic muscle spasm, proprioception change/neuropathy leading to repetitive trauma, arterial impairment (DM – profunda, tibials).

Treat:

- Off load –
 - orthotics, total contact cast, podiatrist/foot specialist
 - MT head resection, Achilles tendon lengthening
- Local wound care and infection.
- Treat underlying d/o
 - i.e. diabetes. R/o PAD/Venous disorder.
- For an ulcer to heal, degree of perfusion may need to be higher for neuropathic limb compared to a limb without neuropathy

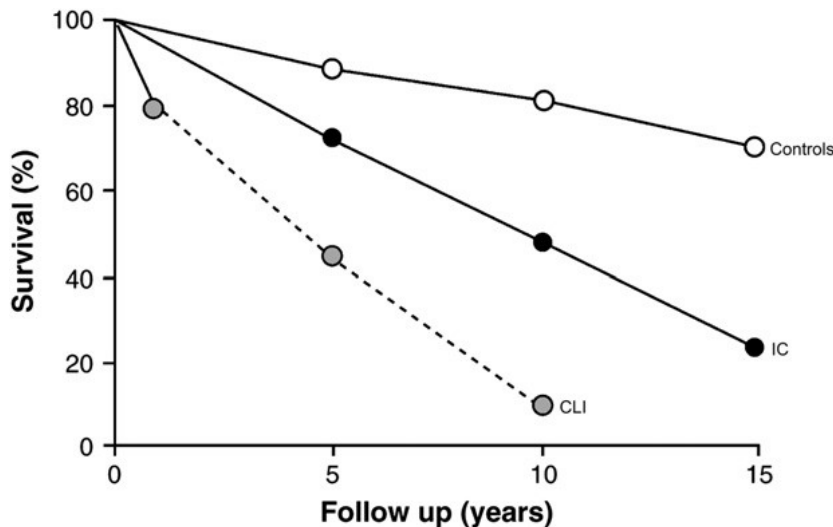
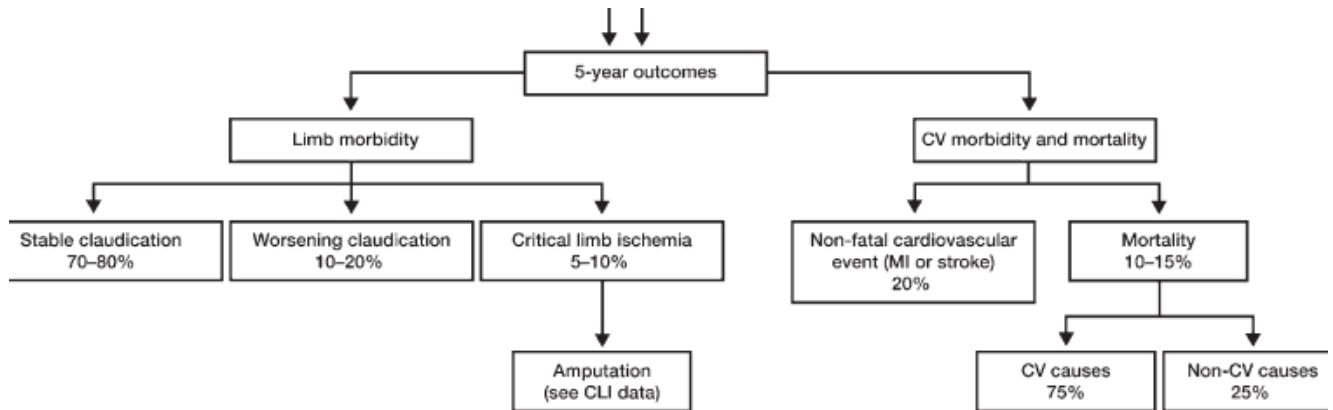
75. 60 yom, claudicant. Conservative management failed. Approach.

- Fate of claudicants compared to non-claudicants?
- Further studies?
- DSA - short segment SFA occlusion
- Mx options,
- indication of PTA, TASC II, discussion about BASIL

Aside:

- IN GENERAL
- 20% deteriorate, 10% develop CLI, 2% lose limbs (more if diabetic).
 - Decrease in ABI < 0.5 is the best predictor of deterioration in IC and mortality

- At 5 years:
 - CV MORBIDITY (non-fatal MI or stroke) 20%
 - CV MORTALITY 10-15%.
- **Risk of limb loss in IC can be stratified:** p. 16, Rutherford
 - It is too simplistic to say for all IC risk of limb loss is 1% per year
 - As is suggested by EPIDEMIOLOGIC data from Framingham
 - **If clinically confirmed, risk of LIMB loss is closer to 5% per year**
 - 3.7% if diagnosis is established clinically
 - 5.8% if diagnosis confirmed with non-invasive studies
 - 8.5 % if ABI between 0.4-0.6
 - Hence term subcritical ischemia



From TASK II:

	Intermittent claudication	No intermittent claudication
5 year survival	85%	95%
10 year survival	50%	85%

ABI <0.5 is an important predictor of overall survival.

Claudication management options:

Goal:

- Increase quality of life
- increase Pain Free Walking Distance, and Maximum Walking distance
 - cilostazole
 - walking exercise
- delay progression to CLI
 - modification of RF
- Thorough discussion re: natural hx of claudication.
 - Generally benign – 20% worse, 10% CLI, 2% limb loss
 - a. See above – may be as high as 8% per year..
 - b. Overall felt NOT to be a limb threatening issue
 - Problem is global: need to address all vascular beds
 - a. i.e. pain in the leg is Life style issue

Management of risk factors:

- interestingly enough, will not affect claudication distance...
 - success in slowing the progreesion of PAD and improving IC *has not been proved* by statistically significant valid clinical trials. Rutherford P. 602
- but it **will address the global progression of atheroscleoris**...
 - has been shown to reduce the risk of CAD and progression to CLI

Specifically, what needs to be done:

- Smoking cessation
 - Smoking improoves IC distance in some but not other studies, hence no consensus
 - Cessation will improve patency of bypass 3 fold...
 - 11% of smokers with IC will undergo amputation, compared to 0% in non-smokers
 - 3 fold higher risk of needing intervention if pt has 40 pack year of Smoking
- HTN control
- HL control

- Reduces progression to CLI
- DM if present
 - Treatment of DM was NOT shown to reduce amputations...
- Antiplatelet medications
- **Walking therapy: the only non-operative treatment shown to improve IC.**
 - Supervised better than non-supervised
 - 150 m difference, Cochrane, 2006
 - 30 min/3 times a week for 3 months,
 - increase to 60 min a session
 - increase speed from 2 mi/h to 3 mi/h
 - initial goal 10 min painful walking then start pushing
 - improvements in walking efficiency, endothelial function and metabolic adaptations in skeletal muscle
 - Cochrane meta-analysis:
 - 150% increase in MWD
 - DRUGS:
 - Cilostazole:
 - decreased platelet aggregation & TG, increased SMC relaxation & HDL metabolism
 - About 140 m (450 f)
 - Rutherford), Taks II – 50-70 m...
 - 30-100% MWD
 - Mc side effect: headache, diarrhea
 - Pentoxifylline: rheologic drug
 - Some studies show benefit, others don't
 - Placebo vs drug: 24% vs 40% in PFWD
 - 32% vs 20% in MWD
 - Overall likely small improvement: 50m (160 f)
 - Operative intervention: bypass vs PTA.

RCT: walking vs endovascular, 2009

- 76 pts ENDO vs 75 pts walking therapy
 - Hospital based
 - Proven mild, moderate and severe Claudicants
- Measure Functional capacity, MWD, PFWD, ABI improvement over 12 months
- Improvement in walking:

	1 week	6 months	12 months
Endo 1st	88%	75%	68%
Walking	16%	77%	65%

Equivalent objective and subjective improvement between two therapies at 3 and 6 months.

Endovascular therapy **does not create new indications** for an intervention.

It defines a population with an accepted indication that allows acceptable improved outcome with lesser intervention.

- Ideal technical outcome of an open bypass:
 - patency, limb salvage and survival
 - **seen in at least 90% of bypasses**
- **Ideal functional outcome after an open bypass:**
 - Hospital free life, reintervention, wound healing, significant change in AMBULATORY potential
 - **seen in only 15% of all bypasses...**
- CANDIDATES FOR ENDOVASCULAR INFRAINGUINAL THERAPY:
 - Economic claudicants
 - exhausted conservative trial of RFM, walking, and cilastazole and who understand that:
 - intervention is done for Life style issues, not limb salvage
 - compared to open intervention, PTA offers an uncertain but reasonable durability
 - compared to open intervention, PTA carries SMALLER chance of conversion to CLI and limb salvage situation
 - patients with CLI with non-prohibitive tissue loss AND limited preop ambulatory capacity
 - despite an excellent anticipated TECHNICAL outcomes of the open bypass in the end are predicted to have suboptimal FUNCTIONAL outcome
 - based on their feeble health status, nursing home situation, poor premonitory ambulation.
 - In these subselected cases, minimal intervention that converts CLI (rest pain or ulcer) to claudication status is worthwhile.
 - SIA as a Technical adjunct to open approach allowing for performance of hybrid cases when purely open approach is either impossible or impractical:
 - TASC II, B type SFA lesion
 - short conduit - SFA/pop inflow source management

- Common fem artery endarterectomy open and SFA angio

If claudicants represent 15% of the operated upon population, then I'd hazard 5% would be task A and B, and hence candidate for endo first option. As far as the CLI it is hard to predict the numbers... 30%?

BASIL: bypass vs angioplasty in severe ischemia of the leg.

Randomized prospective trial

- 27 UK hospitals
- 450 pts with CLI were randomized
- Bypass vs PTA as 1st treatment with CLI due to infra-inguinal disease
- Crossover of patients was allowed after randomization
- Two strategies “broadly similar” wrt
 - amputation free survival,
 - all-cause mortality
 - quality of life in the SHORT term.
 - Surgery 1/3 more expensive
- Kaplan-Meier plots for long term:
 - amputation free survival and all cause mortality favour PTA 1st for the first 2 years,
 - bypass was better past 2 years.
- Overall, at the end of 3 years,
 - **Surgery – 57% amputation free survival**
 - **PTA – 52% amputation free survival**
 - **Overall longevity - 50%**
- **Hence, if life expectancy is less than 2 years, offer PTA.**
- **If life expectancy more than 2 years, offer surgery .**

76. Claudicant in 50 yom:

- work up and treatment of unilateral iliac disease.
- Angio shown.
- When to stent
- TASC II guidelines?

First, optimize RF and get walking therapy for at least 3 months

Assess for need to intervene

- Economic claudicant
- Understand this is no limb salvage
- Understands complications and benefits
- Discuss Dutch RCT for walking vs endo

Review task II guidelines

Stent for HD sig dissection

Notes:

○ **TASC classification for iliac :**

○ Iliac: need to know only A and B – as these are for endo, the rest is open...

- A
 - CIA stenosis: uni or bilateral
 - EIA stenosis <3 cm: uni or bilateral
- B
 - < 3 cm aortic stenosis
 - Unilateral CIA occlusion
 - Unilateral EIA occlusion
 - Not involving IIA or CFA
- C
 - b/l CIA occlusion
 - b/l EIA stenosis not extending into CFA 3-10 cm
 - uni EIA stenosis extending into CFA
- D
 - Infrarenal occlusion
 - Aortic Aneurysm
 - Uni stenosis of both CIA/EIA
 - b/l occlusion of EIA

○ **TASC guidelines for SFA**

- A
 - Single stenosis <10 cm
 - Single occlusion <5 cm
- B
 - Multiple stenosis/occlusion < 5cm each
 - < 5 cm calcified
 - Single stenosis < 15 cm, not involving pop
 - **Single or multiple lesions in the absence of continuous tibial vessel involvement**
 - **To improve inflow for distal bypass**
- C
 - Multiple stenosis/occlusion >15 cm
 - Recurrent stenosis/occlusion after 2 endo treatments
- D
 - Entire SFA occluded
 - Pop or trifurcation occlusion

77. Outline conducts of insitu bypass:

- Review indications, operative fitness, anesthesia assessment
- Image and Agree on type of procedure, inflow, outflow, map vein
- Discuss consent in detail, x-match, mark limb, preop ABX
- Regional anesthetic, Supine
- Dissect proximal inflow
 - Decide if need to do profundoplasty
 - ID and dissect GSV proximally
- Bend knee and dissect distal GSV, then target artery
- Heparin, oversee SFJ, excise proximal valve and construct proximal anastomosis
- Straighten leg, transect distal GSV, use LeMaitre valvulotome
 - While injecting, cut valves in the vein except in the last 2 inches of the graft
 - Use insitu Mill's valvulotome to cut very distal valves
- Ensure good flow through graft
 - If not, may do graftogram now to ID branches and get these through skip incisions
- Orient vein graft, mark.
- Check ACT
- For distal vessels
 - exsanguinate limb with eschmark, 300 mm Hg to thigh,
 - straighten limb, arteriotomy, cut vein to size, do distal anastomosis
- for popliteal, may just clamp and sew
- completion angio

- reverse heparin, hemostas, closure

5 year patency according to TASC II:

- 90% group:
 - Aorto-bi-fem
- 70% group:
 - Fem-fem
 - Fem-pop BK vein
 - Iliac-PTA
 - Ax-bifem
- 50-55% group:
 - Ax-unifem
 - SFA angioplasty for stenosis (no stent)
- 40% group:
 - SFA angioplasty for occlusion (no stent)
 - Fem-distal bypass
- 30% group:
 - Fem-pop-BK prosthetic

Other info re patency: OPEN SFA BYPASS RESULTS according to TASC II. 5 year.

	Claudicant	CLI
Vein	80%	65%
AK PTFE	75%	50%
BK PTFE	65%	65%

Results of SFA endovascular patency according to TASC II, cumulative

	1 year	3 year	5 year
PTA: stenosis	75%	60%	55%
PTA + stent: stenosis	75%	65%	-
PTA: occlusion	65%	50%	40%
PTA + stent: occlusion	70%	65%	-

78. Post BK fem-pop in situ bypass for rest pain. Pt has recurrence of symptoms.

- Post operative surveillance, rationale, protocol
- criteria for stenosis/failing grafts
 - DUS mid graft velocity of >300cm/sec with Vr of >6
- Are there any trials that suggest that routine surveillance is beneficial?
 - Yes, 15% improvement in patency
- DSA shows smooth narrowing at anastomosis. Nature of lesion?
 - What is neointimal hyperplasia?
- Management of distal anastomotic stricture.
 - Ideally, open revision with vein patch
- Would you angioplasty this lesion? Justify your position.
 - Better results with open
 - Only in high risk pt, short lesion
- How to perform open repair?
- What are criteria for angioplasty?

Plan:

- Admit, heparin, angio.
- Angio showed occluded SFA. Proximal vein graft patient. Mid graft, retained valve.
- mark lesion AND donor vein pre-op with duplex so you know where to make incision.
 - May need to replace distal portion of the graft if thrombosed with more distal arterial target

Notes: Graft surveillance

- 15-20% of graft fail within 5 years
 - 10 % - see failure in first 30 days:
 - Poor quality vein
 - Poor anastomosis
 - Poor outflow/inflow
- **In up to 60% of early failure are due to graft lesions**
 - Poor vein vs valve vs twist vs anastomotic narrowing
 - **Technical errors responsible for 4-25% graft failures**
 - **At exploration, 50% of grafts have no apparent problems.**
- Failure in first 2 years:
 - Mostly due to intimal hyperplasia
- IT is critical to detect failing graft:
- Most veins don't stay open after mechanical thrombectomy or thrombolysis
 - Patency after thrombolysis is 20% at 1 year

- At 1 year, 50% are amputated, 25% have rest pain, 15% dead...
 - But limb salvage may be better
- Surgery is a better option if:
 - Taken to OR immediately
 - Mechanical problem is detected (twist, valve cusp)
- Traditional ways to detect failing graft lack sensitivity
 - Recurrent symptoms
 - Loss/reduction of pulses
 - ABI change of > 0.2
 - PPV 12-34%, i.e. LOW
- 8% of lesions develop in first year
 - Lesions developing in first 3 months are more threatening than late ones
- There is 2-4%/year late graft stenosis IN ADDITION to 10% life time risk of progression of atherosclerosis.
- First surveillance duplex study: at discharge or 1 month,
 - then biannually for 2 years,
 - then annually for life
- Check graft velocity, PSV in the lesion. Grade risk level.
- Revise grafts at high risk

RISK LEVEL	HIGH-VELOCITY CRITERIA	LOW-VELOCITY CRITERIA	ABI REDUCTION
Highest	PSV > 300 cm/sec or Vr > 3.5 <i>Or</i> EDV > 100 cm/sec	GFV < 45 cm/sec	<i>or</i> > 0.15
High	PSV > 300 cm/sec or Vr > 3.5	GFV > 45 cm/sec	<i>and</i> < 0.15
Intermediate	PSV 180-300 cm/sec or Vr > 2.0	GFV > 45 cm/sec	<i>and</i> < 0.15
Low	PSV < 180 cm/sec	GFV > 45 cm/sec	<i>and</i> > 0.15

ABI, ankle-brachial index; PSV, peak systolic velocity; Vr, ratio of the PSV within the lesion to the PSV in a proximal normal segment of the graft; GFV, graft flow velocity; EDV, end-diastolic velocity.

- Grafts at risk: these need angio and likely revision....
 - low-flow velocities in the graft
 - peak systolic velocity < 45 cm/sec throughout the graft
 - PSV > 300, EDV > 100
- These need to undergo angiography:
 - **drop in ABI exceeding 0.15 in the absence of detectable graft lesions**
 - need arteriography to search for inflow, outflow, or missed graft lesions
- Grafts with low and intermediate risk – follow: q 3 months
 - 50% of these will progress.

Vein graft surveillance improves long-term vein graft patency by approximately 15%

- RCT by Lundel, multiple observational studies
- Cost effective (multiple studies)

In general, open repair with patch or interposition gives best results.

Candidated for angioplasty:

- Vein diameter >3.5 mm
- Lesion length < 2 cm
- Appearance more than 3 month after original surgery

Operative plan for thrombosed infrainguinal graft:

- heparinize
- if situation allows do angio in angiosuite
- otherwise, go to OR
- evaluate inflow
 - r/o embolus, clamp injury, anastomotic problem
 - incise hood of proximal anastomosis, do thrombectomy
 - evaluate anastomosis
- thrombectomise graft, angio
 - assess for valves, kinks, stenosis, look at distal anastomosis and outflow
- if necessary, expose distal anastomosis as well, revise if necessary
- may need to do jump graft to distal target

79. 60 yom with acutely ischemic left leg. DDX and management:

Brief Hx:

Canadian Vascular Surgery In-Training Cases, U of Ottawa, Anton Sharapov, MD, 2008

Limb:

- acute onset? 4 Ps of HX: Pain? Paresthesia?paralysis?cold?
- previous claudication (prev atheroembolism)?
- Prev vascular problems (bypass, AAA)

ROS:

- Rapid heart beat, irregular heart beat, diagnosis of AF, recent MI,
 - embolism
- Hx of hypercoagulability, Vascular surgery, known stenosis/AAA/pop aneurysms
 - thrombosis
- Recent knee surgery/trauma
 - trauma
- Searing back pain
 - dissection
- RF: HTN, HLD, smoking, homocysteine, DM, (atherosclerosis)
- RF manifestation: prev CVA/TIA/MI/vascular surgery
- RF tx: drugs (ASA/statin/ACEI/BB), sugar control, HTN control
- PSH, PMH, allergy, FH.

Brief exam:

- Vital signs and Heart rate/ECG
- Extra HS

- Arterial bruits
- Abdominal aneurysm
- 2Ps (signs) :
 - pale
 - pulseless
 - Doppler Venous & Arterial, palpable, ABI
- Tender calves/myositis
- Signs of PAD, scars, ulcers, etc.

DDx:

Causes of arterial occlusion in general:

- embolism
- thrombosis
 - pre-existing occlusive disease
 - hypercoagulable state
 - thrombosis in normal vessels
 - congenital, malignancy, post-op, trauma
 - trauma & dissection
 - disruption of normal vessel
 - outflow occlusion
 - blood flow backed up leading to thrombosis
 - low flow state
 - sluggish blood flow leading to thrombosis

Causes of popliteal a. occlusion:

- Embolus
- Thrombosis
 - atherosclerosis
- Popliteal aneurysm
- Trauma
 - knee surgery, disarticulation
- RARE

- Buerger's
- Pseudomyxoma elasticum
- Pop entrapment
- Cystic adventitial disease

Plan:

- ALI classification,
- foley, fluids, start heparin,
- studies/labs:
 - ECG, Doppler pop fossa in ER,
 - CBC (Hg , Htc, WBC), Cr (for angio), lytes (metabolic problems),
 - CK & urine myoglobin (myositis),
 - CXR, cross match, PT/PTT
- Classify ischemia and plan accordingly:
 - angio vs OR/on table angio

Acute limb ischemia classification, Rutherford:

- Category 1:
 - viable, no motor/sensory loss, arterial Doppler present
 - may do angio
- Category 2a:
 - marginally threatened, some sensory loss, no motor loss, no arterial Doppler signal, but venous signal present
 - may do angio
- Category 2b:
 - immediately threatened, motor/sensory loss present
 - have to go to OR, then angio on table
- Category 3:
 - irreversible, anesthetic, paralytic, no arterial AND venous Doppler.
 - Too late, amputation

Signs suggestive of irreversible loss:

1. Fixed cyanosis
2. Marbled mottling

3. Myositis: dough consistency, calf pain, muscle rigidity
4. Anesthetic sensory loss
5. Complete paralysis
6. No spontaneous venous Doppler
7. Fixed ankle

In this case pathology is thrombosed popliteal aneurysm. Approach?

Viable foot: class 1 and 2A:

- no good run off vessel –
 - anticoagulate, consider 48 h CDT, then reassess for OR
- has run off vessels –
 - anticoagulate, semi elective repair

Threatened foot: class 2B:

- no run off vessels –
 - immediate OR for thrombectomy, intraoperative thrombolysis, then bypass
- has run off vessels –
 - immediate OR for GSV bypass

For very high risk patient, consider stent.

Aside:

Popliteal aneurysm:

- Male, elderly pts – 6-7th decade
- 50-70% are bilateral
- 30% have AAA
- Rate is higher if pop aneu are bilateral
 - 30% have fem Aneu
 - 40% involve tib/per trunk
 - Classification:
- Fusiform vs saccular
- Prox, mid, distal
 - Asymptomatic in 45%
 - If symptomatic:
- Ischemic (progressive embolization, thrombosis)
- Local
 - Pop mass
 - Pain
 - Venous compression/edema/phlebitis
- When to fix:
- All symptomatic

- Asymptomatic > 2 cm
- If perimural thrombus
 - Particularly if outflow is reduced – atheroembolism...

Operative approach:

- Endo vs open
- Single small RCT showed equivalence of results
- Antonello, 2007 update

		Open 27 pts	Endo 21 pts	p
12 months	1°	100%	86.7%	NS
	2°	100%	100%	NS
72 months	1°	71.4%	88.1%	NS
	2°	88.15%	85.9%	NS

- Open:
 - Medial vs posterior approach
 - Huang, 2007, 4 year
 - Primary patency 85% (vein), 50% (ptfe)
 - Secondary patency 94% (vein) vs 63% (ptfe)
 - Consider intraoperative thrombolysis/isolated limb perfusion
 - Open: Medial vs posterior approach
- If elective, <1% mortality and limb loss
- If emergent 5% mortality and up to 20% limb loss.
- Predictors of complications:
 - Diameter of aneurysm > 2cm
 - Thrombus in lumen
 - Poor outflow

Open approaches to pop aneurysm repair: advantages and disadvantages

Medial:

- ADVANTAGES:

- easy GSV harvest,
- supine/not prone position – easier for GA,
- familiar approach,
- can get far remote and distal access to SFA/trifurcation
- avoid tib/peroneal nerve
- **DISADVANTAGES:**
 - Saphenous n. injury
 - Difficult to get into aneurysm
 - Long scar

Posterior:

- **ADVANTAGES**
 - Easy access to aneurysm
 - Can do interposition repair
 - Easy access to LSV
 - Extended distal exposure
 - Cosmetic incision
- **DISADVANTAGES;**
 - Unfamiliar territory
 - Pop vein and tib/per nerves in the way – injury potential
 - Can't go far proximal
 - Can't easily get GSV
 - Prone position – more difficult to GA (risk to eyes and airway loss)

Nerves encountered in popliteal a. exposure:

- Tibial
- Medial sural – off tibial
- Common peroneal
- Lateral sural - off common peroneal

- Overall survival:
 - 60-85%, depending which study to look at
- Patency – 5 y:
 - 55% sympt, 90% if asymptomatic
- Vein BETTER than dacron/ptfe
- Don't tunnel behind popliteal – you'll compress the graft, so go subcutaneous
- Don't hesitate to inject 2.5- 5 mg tPA into each AT and TPT, clamp it, go away to dissect the GSV from thigh
- Confirm clearance with angio, and if good outflow, do END –to – END anastomosis to distal pop. Do shortest bypass form distal SFA and ligate above and below knee pop.
- Assess for fasciotomy

Note that this scenario usually begins as innocently enough as a typical case of embolus EXCEPT there would be NO obvious source of embolus. In such case, ALWAYS state that while you are concerned with embolism, you also worry about popliteal source thrombosis with usual suspects (aneurysm, atherosclerosis, W&W (pop entrapment, ACD, burger, etc...)) Then Check for CL pop aneurysm and AAA aneurysm post op as there is high (50-70%) incidence of bilaterality AND 30% incidence of AAA.

80.60 yom with sudden onset of bilateral painful lower extremities

- DD
 - Non vascular:
 - Spinal cord injury vs stenosis
 - DM neuropathy
 - Complex regional pain
 - Embolus
 - B/l CFA embolus taking out profunda/SFA
 - Saddle embolus at aortic bifurcation
 - Clot
 - Tumor
 - Aortic dissection
 - Thrombosed diseased aorto-iliac segment (AIOD)
 - End-to-End ABF graft went down
 - b/l thrombosed pop aneurysm
- Approach
 - Resuscitate with fluid, start heparin then assess:
 - Circumstances: sudden (embolic) vs gradual (thrombotic)
 - degree of ALI, classify
 - premorbid mobility, functional capacity and longevity
 - PVD factors, previous bypasses, AF, recent MI,
 - previous imaging
 - if embolic – may take to OR right away without imaging, if thrombosed, try to image first to plan outflow improvement
 - If 2B – explore in OR,
 - prep neck to ankles
 - embolectomy/angio and ABF/AxBF
 - If 2A and above, may image first to decide

81.When do you do thrombolysis in thrombosed popliteal artery aneurysm?

- If aneurysm is completely thrombosed, outflow is poor *AND there is no acute ischemia to allow for gradual reperfusion* then percutaneous thrombolysis may be attempted:
 - Severe irreversible deterioration can occur in 2.3% - probably more often if aneurysm is thrombosed
 - Mild deterioration seen in 13% -
 - resolved with continued thrombolysis
 - Essential to cross the clot and saturate it to allow tPA contact with plasminogen
- Threatened foot – and no outflow after operative exploration:
 - Intraoperative thrombolysis.

On exam, I'd be hesitant to cross thrombosed pop aneurysm. I'd rather control it distally, do mechanical thrombectomy and intraoperative lysis if needed.

82. Patient with AF and chronic PVD. Numb/paralyzed foot for 3 hrs.

Likely femoral artery embolus. Management?

- Prep both legs as unaffected side has good pulse.
- Do embolectomy.
- Good inflow but fogarty won't pass distally.
- Expose BK pop and tibial origins.
- Fogarty thrombectomy/embolectomy:
 - The bigger the number the bigger the size
 - Diameter=twice the number...
 - 5 – 11mm
 - 4 – 9 mm
 - 3 – 5 mm
 - 2 – 4 mm
 - 2 -3 for SFA/below knee
 - 4-5 for iliacs and aorta
- Can't get fogarty down
 - Describe Intra-op TPA
 - Intra-op angio after TPA attempt
 - Posterior tibial is open
 - bypassed with GSV from BK pop to PT

aside:

Intraoperative thrombolysis:

- After thrombectomy is done – do angio.
 - If clot is gone – occlude artery and bolus IA lytic in distal bed
 - 2-8 mg tPA or 100,000-250,000 urokinase to open up collaterals
 - Incomplete thrombus – either repeat bolus or restore perfusion and start IA drip with catheter (less ideal)
 - Extensive residual thrombus –
 - Isolated limb perfusion
 - Exsanguinate limb with eschmark's bandage
 - 250 mm blood pressure cuff to thigh
 - Canulate pop vein with red rubber cath
 - Canulate AT and TPT
 - Infuse 500,000 uro or 50 mg tpa into each artery in 500 cc of NS over 20 min
 - Drain vein, flush out with another 1 L NS/heparin
 - Restore circulation
 - Can keep cuff for up to 1 h
 - Most of plasminogen activator escapes via vein. Some will go into bone marrow ->systemic

83. 50 yom, claudication on R: no pop pulse, large pulse in L pop fossa:

Work up revealed AAA, b/l pop aneu.

- Treatment and plan.
 - AAA treated on its' own terms
 - R pop – aneu
 - Assess outflow
 - Control distal pop
 - Thrombectomy +/- intra op thrombolysis (see Minimum notes)
 - Medial approach
 - CL pop aneurysm – fix if
 - Evidence of athero/thromboembolism
 - > 2 cm
 - Thrombus in aneurysm
 - Note, if pt has stable IC and thrombosed pop aneurysm, some may argue that ligation of aneu is all that is required...

84. Diabetic foot with gangrenous toe:

b/l moderate claudication, prev b/l GSV/LSV stripping, **heart attack 2 months ago.**
Management?

- Foot:
 - Ask re: open wound, discharge, pain,
 - degree of disability, claudication,
 - treatments provided, abx,
- General:
 - fever/chills/sweats,
 - control of DM,
 - cardiac status (needs cardiology f/u, CABG, plavix, echo, etc?),
- review ambulatory ability, RF, RFM, RFtx, prev surgeries.
- All/FH/drugs

O/E:

- general/VS/HS/bruits/AAA/prox/distal pulses/neuro exam
- Foot:
 - swelling, ulcers, drainage, exposed bone, deformity, stigmata of PAD, CVI, scars
- Lab: routine lab, Hg A1C, wound culture, blood culture
- Inv: plain foot xray, if bone is not exposed – bone scan, ABI/toe index.

Plan:

1. if septic – fluids/Broad spectrum abx, I&D, debride, guillotine amputation if required then culture specific antibiotic
2. otherwise, conservative dressing change till 6 months, at which time r/a healing potential and need for revascularization
3. if need to perform surgery immediately, involve cardiology/anesthesia – pt is less than 6 months post mi – needs optimization.
4. Regardless of what's done surgically, needs aggressive RF modification.

Possible variation of scenarios include presence/absence of infection/pulses. Presence of neuropathy makes ulcer treatment more difficult.

85. 32 year old male, with retinal hemorrhage, CAD and b/l IC:

Dx and 3 clinical features

- this is pseudoxanthoma elasticum...

Pseudoxanthoma elasticum:

- CTD causes elastin degeneration -> calcification
- 70% of patients less than 35 yoa
- Skin, eye, cardiovascular system
- Xanthomas along neck/groin flexion lines (chicken skin)
- Spontaneous retinal hemorrhages -> blindness
- Early AGRESSIVE diffuse atherosclerosis
 - CAD
 - a. Don't use LIMA/RIMA, only GSV...
 - Stroke
 - Soft tissue calcification (elbow, hip)
 - a. Dd trauma, scleroderma, hyper PTH

Tx: very tight control of RF, otherwise treat as usual...

86.35 year old male smoker with gangrenous 1st and 2nd toes:

- Rest pain, night pain, history of claudication.
- Differential diagnosis of CLI (specifically in young patient).
 - embolus
 - Dissection
 - Adventitial cystic disease
 - Entrapment
 - Pseudoxanthoma elasticum
 - FMD
 - Buerger
 - Trauma
 - Endovascular fibrosis – usually external iliac involved
- Duplex:
 - Angio showed normal proximal vessels to popliteal. Tibial vessels occluded.
- Diagnosis:
 - Buerger's disease
- Angiographic criteria for Buerger's disease.
 - No atherosclerosis
 - Infrapopliteal disease
 - Segmental disease
 - Vasa-vasorum collaterals (cork-screw)
 - Appearance not suggestive of embolus
- Pathological findings in blood vessel

- thrombus is *inflammatory*
- inner elastic *lamina is spared*
- no acute phase reactants (unless acute infarction of limb)
- markers of immune-activation are absent
- discontinuous lesions
- diagnostic criteria:
 - distal arterial disease
 - WITH smoking
 - WITHOUT DM, lipid, HTN, embolus, CTD, myeloproliferative disease, hypercoag state

Treatment:

- Stop smoking, pain management, ASA, CaCB, iloprost, debride, bypass or amputate if necessary.
- Wound care, drug therapy, TENS, role of sympathectomy, surgery.
- Amputation rate in smokers – 43%, ex-smokers – 6%

Aside:

Buerger's disease diagnostic criteria:

- Onset < 45 yoa, m>>f
- Smoking hx
- Infrapopliteal/infrabrachial arterial involvement leading to ischemia documented clinically (RP, ulcer) and objectively
- No other RF for atherosclerosis (DM, htn, lipids)
- Exclusion of ... by echo and angio...
 - proximal embolism (cardiac, TOS, aneu, arch, athero)
 - trauma
 - local lesions (adv cyst d, pop entrapement)
- Lab test exclusion of autoimmune, CTD, DM, myeloproliferative DO
- Other:
 - Migratory phlebitis, Raynaud's, instep claudication

Etiology:

- smoking, genetics, hypercoag and endothelial dysfunction, immunologic mechanism

87. 30 yom, short distance claudication:

- Differential
 - Pop entrapement, Cystic adventitial disease, Pseudoxanthoma elasticum, dissection, trauma, Buerger, FMD

- Angio – cystic adventitial disease.
 - Scimitar sign and hourglass sign
 - No atherosclerosis
- Treatment?
 - posterior approach,
 - open I&D,
 - if fibrosed – interposition graft
 - no role for US guided percutaneous drainage – recurrence rate too high.

88. Fever and chills 3/52 after R iliac stent. CT shows air around CIA.

- Approach
 - Review initial indications for a stent
 - Review pt current sxs and stent status
 - This will determine the need for reconstruction
 - If stent is occluded, and pt is fine, the no need to reconstruct
- Treatment:
 - Infected graft approach
 - IV abx
 - Blood and groin/CT (if applicable) cultures
 - Debrided, drained, post op ABX
 - May need RP cut or laparotomy
 - fem-fem vs ax-fem tunneled in clean plane
 - only if critically ischemic
 - Indications for in-situ reconstruction with SFV.
 - No sepsis or positive blood cultures
 - Only St. Epi in biofilm
 - No graft-enteric fistula

89. General surgery resecting cecal tumor. Find the mesentery is attached to the R CIA.

- Intraoperative consult
- Assess hx and preop vasc status, RF
- This is locally advanced colon cancer, T4
 - Possibility of good survival is there if no lymphnodes or mets
- Do preliminary preparation:
 - **Ask anesthesia re: stability, blood loss, xmatch, blood on hand**
 - **Inform that more blood may be lost**
 - **Ask for vascular instruments**
 - **Top up antibiotics**
 - Consent:

- Inform power of attorney re: need for vasc reconstruction and greater extent of surgery
 - Possibility of limb loss, possible fasciotomy, impotence issues etc
 - Assess on CT extent of tumor involvement
 - Ureter? L CIA? Etc...
- Dissect the tumor down to its' CIA attachment
 - See if possible to develop clean plane above adventitia
 - Otherwise:
 - consider resection of anterior wall vs entire CIA
 - Preserve ureter
 - Prox/distal control
 - Heparin
 - Patch with bovine pericardium or vein
 - If decided to resect:
 - ligate prox and distal R CIA
 - see if can leave posterior wall in place
 - Watch out for Left CIV
 - Vein reconstruction vs fem-fem after laparotomy

90. Patient went for coronary angio. Develops ischemic leg post procedure.

You are called 2 h later. Barely moves the toes, paresthesia.

- DD
- Management,
- type of anesthesia,
- need for angio pre-op etc.

- Review indication for the original cath –
 - MI vs angina vs work up for valve surgery, diagnostic, interventional,
 - If post recent MI, may limit your choices of OR

- Assess for high stick problem, use of angioseal, current use of antiplatelet agents
- Review pre-morbid PVD factors, ambulation and fitness
- Review extent of ALI – this looks like 2B...
- Review old imaging or obtain new one in OR
- Heparinize and resuscitate
- Plan to put a single stitch
 - but be prepared for
 - RP incision for proximal control
 - If sheath in CL extremity is present, may consider up and over balloon occlusion instead...
 - Patch angioplasty

- If inflow problem:
 - Plan for ax-fem possible fem-fem possible iliofem

91.R groin thrill on exam post cardiac catheter. Approach:

- Iatrogenic (post procedure)
- Non-iatrogenic (true trauma)

If central in origin, unlikely to close, so will require repair.

If peripheral and is NOT associated with true trauma (i.e. iatrogenic origin post needle stick), 90% will close in 4 months (average length of closure is 28 days).

Indication for repair:

- Fluid overload
 - Venous HTN
 - CHF
- Distal ischemia
- Non-compliant patient
- Central location/neck
- Post trauma (as opposed to procedure)

General recommendation is to wait 4 months unless there are indications (above). Repair failures. Proximal and distal control. Expect major blood loss.

TRAUMA:

92.MVA and iliac artery injury.

Blunt abdominal trauma, lap belt bruising, peritonitis, L flank bruising, ischemic L leg and no femoral pulse. Approach?

ABCD, CXR, x-match, foley, NG, abx/tetanus/resuscitation.
AMPLE hx, vascular procedures, RF inquiry when stable.

Exam:

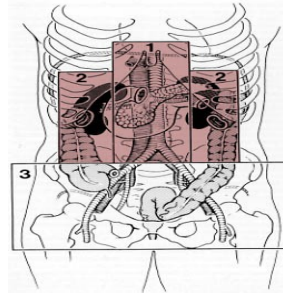
- Head to toe first
- Neuro vascular of LE

Overall principle: don't forget to look for OTHER injuries – i.e. carotid, aortic, pelvic #, extremity etc. Do not forget about x-match, abx, tetanus, and Life over Limb principle

Lapartomy is carried out by general surgery.

- Non-expanding hematoma in RP, zone 3

Aside:



- Thrombosed 5 cm CIA. 2 scenarios:

1. colonic spillage:

- Hartman's vs primary repair for bowel injury (<6h, blood loss <6 units, HD stable, minimal spillage, minimal tissues).
- Assess L leg – if NOT immediately threatened – good distal signals, decent ABIs, observe.
- Otherwise, Fem-fem for with PTFE.

2. No colonic injury: IF leg is threatened, do either fem-fem or ilio fem (PTFE) – dissect proximal CIA. Most people would go for fem-fem as iliofem would require entrance into hematoma.

If pt is going to be intubated and unconscious OR > 6 hours after injury passed – do prophylactic fasciotomy. If pt is conscious and less than 6 h passed – careful monitoring for compartment – clinical, urine myoglobin, u/o.

Important variation:

- Blunt injury, no evidence of peritonitis, CT shows thrombosed L CIA, RP hematoma around. no intraabdominal fluid, injury, stranding etc.. Having ruled out need for laparotomy, many proceed directly to fem-fem. Don't try to explore abdo first...
- you'll have to do lapartomy first if it is penetrating injury. If doing laparotomy you see zone III hematoma, even for blunt injury, if there is evidence of leg circulation compromise, you have to explore it.
- **Aside, according to Rutherford (p. 1039), one of the indications for RP pelvic hematoma exploration, is absence of femoral pulse... Iliofemoral reconstruction with**

Canadian Vascular Surgery In-Training Cases, U of Ottawa, Anton Sharapov, MD, 2008

PTFE or SFV would then be in order... However, several surgeons I talked to advise against exploring the abdomen and recommend proceeding with fem-fem. FF will have suboptimal hemodynamic results but certainly is safer. While you worry about back perfusion of the ruptured vessel, most surgeons won't ligate distal EIA hoping it has thrombosed...

- Ilio femoral bypass - You may want to do this ONLY if there is no pelvic fracture injury and pt is completely stable.

93. Middle aged female, MVA and aortic injury

Pt went to OR because of hypotension and splenic /duodenal injury. Needed splenectomy, clean up of spillage of enteric contents from duodenal injury which is now repaired. You are asked to see her because of possible aortic injury.

CT scan was done preop showed mid/distal aortic dissection extending into the proximal left CIA. Intact pulses pre-op with no evidence of ischemia. You examine the retroperitoneum and note some bruising/discoloration of the retroperitoneum but no expanding, pulsatile hematoma. The pulses in the iliacs and femorals are strong.

- Next?
 - do nothing...
 - blunt trauma with no evidence of pulsating/expanding hematoma, bowel ischemia or limb ischemia.
 - Close pt.
 - get a CT scan the next day to check for pseudoaneurysms
 - follow her with US or CT

Notes on Abdo vascular trauma:

Korean/veietnam war – 3%

Civilian:

- Penetrating:
 - gun shot – 14%, stab 10%
- blunt 3% (MC renal, then sma)

Retroperitoneal hematoma:

- Explore all penetrating
 - Exception – stable perinephric NOT involving the hilum
- Blunt: explore only if
 - Leaking

- Expanding (some say only RAPIDLY expanding)
 - Pulsatile
 - Paraduodenal
 - Root of mesentery (i.e. SMA) **PLUS ischemic bowel (p. 1032)**
 - Bladder/male urethral injury/pulseless leg in zone 3
- Unexplored hematomas are to be followed by Doppler.
 - Enteric spillage is not contraindication to prosthetics
 - Supra mesocolic a.control – L visceral rotation, diaphragmatic control, L chest
 - Inframesocolic hematoma-
 - Transverse mesentery reflected cephalad,
 - small bowel to the R
 - mobilize duodenum
 - ligate IMV.
 - Hematoma around SMA –
 - retropancreatic portion (may transect neck, or supraceliac proximal control),
 - infrapancreatic portion –
 - transverse mesentery reflected cephalad, assess for presence of dead bowel
 - if pt is stable, and no pressing need to explore – then image it post op
 - otherwise, have to explore **ONLY** if bowel is necrotic and/or jeopardized
 - high risk of collateral damage with exploration
 - see p. 1032, 1036, fig. 72-13.

When is it safe to ligate a mesenteric vessel –

- SMA - do trial clamping and consider ligation **ONLY** at the origin –
 - i.e. above gastroduodenal and inferior pancreaticoduodenal arcade.
 - Ligation elsewhere – high incidence of bowel ischemia.
- Celiac – ok to ligate if SMA is ok
- CHA – proximal to take off of GDA.

94. Bike accident. Occluded distal axillary/proximal brachial artery (transected).

Anatomy of subclavian and axillary artery?

- Subclavian:
 - Vertebral, IM, Thyrocervical, costocervical, dorsal scapular (50%)
- Axillary – 3 segments
 - Higherst thoracic,
 - lateral pectoral, thoracoacromial,
 - subscapular, ant/post circumflex
- i.e. large potential for collateralization

Management options?

- Don't zero in on the extremity vasculature, it's a trauma situation
 - May have OTHER vascular and nonvascular injury
 - First consider stability of pt
- Usual trauma preliminaries:
- ABC, xmatch, tetanus, abx
- Then assess level of neurological function
- Pts handedness, occupation, hobbies, associated med condition

- If limb ischemic AND good hope for neuro recovery - need to fix
- If stable, may choose to observe

- When to fix?
 - If hard signs
 - Active bleeding (internal, external)
 - Bruit/murmur
 - 6 Ps
- Otherwise – correlate clinical with angio
- consider angio first if soft signs

- Operative approach?
- Discuss CONSENT, complications, manage expectations
- Ideally C-arm and angio table
- Supraclavicular incision for subclavian a.
- Infraclavicular for axillary
- Proximal brachial cut down
- How to get proximal control before entering hematoma.
 - May consider endovascular balloon vs proximal control with supraclav incision vs sternotomy for RCA/ posterolateral thoracotomy fo L SCA
- What if he had L subclavian injury?
 - Proper exposure is postero-lateral thoracotomy to get to the origin of LSA

95. Young male, MVA, Polytrauma, chest trauma

- primary survey done.
- CXR: widened mediastinum, chest tube initially 200 cc, then stopped. Patient hypotensive - needed laparotomy to stop intraabdominal bleed (pancreatic/duodenal injury).
- Approach?
 - Stabilize abdominal and neuro injury first
 - Assess with imaging

- Large vessel injury can wait
 - If it can't pt is usually dead by then...
- CTA: see descending aortic injury.
- Options:
 - observe (if minimal intimal tear) vs fix (aneurysm/all layer tear)
- Short proximal landing zone, have to cover L SCA. Is it ok?
- Yes, unless:
 - Prominent/dominant Vertebral
 - LIMA graft is present
 - Extensive coverage of the descending thoracic aorta – i.e. T9-L1
 - Prev AAA repair (lumbar and IMA collaterals are gone)

What complications of endo to expect? How are you going to deal with it?

Can still develop spinal ischemia, plus usual EVAR complications

Aside: approaches to chest...

- Ascending aorta and arch – require full cardiopulmonary bypass, hypothermia and cardioplegic arrest
 - Aside: arch vessels may be reconstructed with side biting clamp to ascending aorta and a bypass
- Distal aorta:
 - Clamp and sew
 - Off load heart:
 - Atrio-femoral bypass (Most common)
 - Axillo-femoral (time-consuming)
 - Full cardiopulmonary bypass (used rarely)
- Aortic trauma repair general points:
 - Pre-warm room and fluids to 40 degrees
 - Prox control btw L CCA and L SCA
 - Watch out for vagus and thoracic duct
 - L vertebral artery takes off arch in 8% of cases
 - Do not debride aorta
 - Do not sacrifice intercostals
 - Move clamp closer to injury
 - Fine suture and knitted graft
 - For grafts taking off ascending aorta, use single limb, multiple if necessary
 - Premanufactured bifurcated are too bulky, may not fit in anterior mediastinum...
 - Use bovine pericardium to cover this

Midline sternotomy: helpful points

- Skin from Sternal notch to xyphoid
- Develop retrasternal plane above and below, no need to connect these
- ASK anesthesia to deflate lungs to minimize chance of pneumo
- Oscillating saw
- Divide thymus
- L brachiocephalic vein:
 - Preserve
 - ligate its' thyroid tributaries
 - will allow mobilization of this vessel.

Anterior thoractomy: for subclavian exposure

- Avoid R sided central lines – may cause pneumo –
 - won't be able to do single lung ventilation
- Double lumen ET tube

- Supine, roll under L shoulder and hip to bring chest up 20 degrees
- L infrapectoral incision
- ID 5th rib, go above it – 4th intercostal space
- Rib spreader – may need to divide internal mammary a/v
- Deflate lung, push it down
- ID arch under mediastinal pleura
- Incise it, preserving L vagus nerve coursing anterolaterally over origin or LSA
- Thoracic duct is posteromedial - preserve

L Postero-lateral thoracotomy: for descending aorta exposure

- Bean bag, strap hips,
- True lateral position, roll under R axilla, L arm over Mayo stand
- Incision from below L nipple to 1 inch below tip of scapular
- Divide serratus ant, lats, trapezius – slide shoulder girdle up
- 4th ICS for middle descending aorta, 6th ICS for distal
- Verify ICS from above by counting
- Protect phrenic and vagus nerves coursing over arch

Open vs endo for thoracic aortic pathology – is stenting still experimental?

- No, accepted lower morbidity modality

- prospective non-randomized TAG trial for repair of descending TAA for aneurysm. No trials in trauma
- FDA Gore TAG trial: applies to thoracic aortic repair

complication	open	stent
paraplegia	14%	3%
stroke	10%	5%
rupture	0%	0%
reintervention	10%	4%

96. 35 yom, MVA, fractured pelvis, ribs, R tib-fib. Asked to see re: ischemic R leg.

- Life over limb:
 - Ask about ABCDE and ensure that the basics are done first
 - Ask them to ensure ABC stability before delving into history
 - Ask for X-match
 - Ask to splint limb fracture, wrap pelvis if unstable
- Evaluate the circumstances:
 - Timing of accident
 - How accident happened
 - Injuries that might suggest OTHER vascular injury
 - Carotids:
 - seatbelt injury to neck
 - flexion/extension
 - aorta
 - 1st rib, scapular, sternal fracture
 - Diaphragmatic rupture
 - Pelvic fracture
 - Assess overall stability
 - Need for life-saving laparotomy
 - Stability
 - Other planned life saving interventions
 - Then go on to limb...
 - Assess preop functional status and PVD/surgeries
 - Hard signs of limb ischemia, ABI
 - Venous signal
 - Assess NEURO
 - Assess tissue loss

- Decide if dealing with MANGLED extremity and involve ortho
 - Evaluate potential for revascularization AND functional recovery
 - If planned to go to OR:
 - Obtain informed consent:
 - Angiogram, Bypass, CL extremity vein harvest, possible fasciotomy
 - Including risk for limb loss, need for revision, death
 - Involve ortho
 - Inform OR, ask for bypass set, warm up the room, ask for blood to be available, C-arm and angio table
 - Who gets to operate first?
 - In general, vascular takes priority
 - If unstable fracture –
 - if less than 4 hours passed and ex-fix can be placed in less than 30 min, may let ortho go first
 - if time is short, then explore the wound first, place shunt, then let ortho do an ex-fix
 - make sure they don't block your medial access to the knee
- in this case ortho put a quick ex fix for tib/fib fracture
 - update abx, supine, GA, prep nipples to toes, b/l legs
 - get angio first from groin (if pulses present, or may go contralateral up an over)
 - on angio see no flow past mid popliteal, reconstitutes PT and peroneal
 - plan:
 - expose distal SFA, control
 - expose infrageniculate pop, medial approach
 - see if you can use heparin –
 - assess other injuries, head injury etc
 - if can, heparinize
 - evaluate pop and tib-peroneal trunk
 - with blunt injury, usually not possible to do a short interposition graft – area is bruised and dissected
 - end up doing short bypass to PT
 - ideally preserve bifurcation of tib-fib trunk to allow back perfusion of peroneal
 - harvest vein from CL groin – easiest surest way to get good vein
 - if concomitant vein injury:
 - see if can repair with simple venorrhaphy
 - if not – ligate, no role for complex reconstruction
 - assessment for fasciotomy

97.40 yom construction worker, isolated knee dislocation, pulseless foot.

Pulses return to normal after reduction.

- How do you proceed?
 - First go over ABC, x-match, tetanus, abx, r/o Life threatening injuries
 - If stable – review hx: IC/RP/ulcers, ambulation, RF for PVD
 - Assess limb: NEURO status, TISSUE loss, mangled limb
 - Assess chances of salvage, discuss with Ortho
 - Only after this - Angio
- What anatomic features of the pop artery make it prone to injury?
 - Relatively fixed by
 - adductor hiatus,
 - geniculate branches,
 - AT artery traversing interosseous membrane
- If decided to go to OR, do the “OR drill”
 - Informed detailed guarded consent
 - Get experienced help
 - Warm OR, blood available, angio table and C-arm
 - Preop abx
 - Positioning, extent of prepping, and discuss which service operates first
- Advantages and disadvantages of approaching this injury through medial and posterior approach.
- Medial:
 - ADVANTAGES:
 - easy GSV harvest,
 - supine/not prone position – easier for GA, no risk for retinal ischemia
 - familiar approach,
 - can get far remote and distal access to SFA/trifurcation
 - avoid tib/peroneal nerves
 - DISADVANTAGES:
 - Saphenous n. injury
 - Difficult to get into aneurysm
 - Long scar
- Posterior:
 - ADVANTAGES
 - Easy access to aneurysm
 - Can do interposition repair
 - Easy access to LSV

- DISADVANTAGES;
 - Unfamiliar territory
 - Pop vein and tib/per nerves in the way – injury potential
 - Can't go far proximal
 - Can't easily get GSV
 - Prone position – more difficult to GA (risk to eyes and airway loss)
 - Wound healing problem
- Describe posterior approach.
 - Prone, protect airway and eyes
 - Lazy S – medial top to lateral bottom incision over pop fossa
 - Go through fascia
 - ID/ligate LSV
 - Protect sural nerve
 - **ID/protect pop vein and tib nerve, reflect laterally**
 - Artery deep and medially
 - Can go distally by splitting head of Gastroc
- Artery is damaged over 5 cm, requires graft interposition. Lesser saphenous vein is small and not suitable for bypass. Next?
 - Reposition for GSV harvest
 - Use prosthetic
 - Suboptimal results
 - Moore et al disagrees.
- Variation:
 - post angio – small intimal damage but duplex showed vein thrombosis. Management.
 - Leave alone, AC
- Why need to do fasciotomies?
 - If repairing both vein and artery
 - After prolonged (>6h) ischemia
 - Sig MSK injury

98.Called to ICU – placed 8 Fr sheath into R subclavian artery. Approach:

Options:

Open:

- Dissect axillary artery
- Dissect subclavian artery
- Be prepared to do sternotomy if can't get proximal to sheath hole...
- Control, pull sheath out, fix hole

Endo and open:

- Proximal control either from sheath or brachial puncture with a balloon in proximal subclavian artery
- The rest is open

Total endo:

- Trying to Perclose with a device may be a too dangerous – you will lose control of the artery the moment you deploy the device.
- i.e. if perclose does not work, then you have noncompressible artery bleeding
- Brachial artery puncture, 5 Fr sheath, wire across the subclavian
- Inflate balloon over the 8 Fr hole, pull sheath
- Wait 15 min (may inject heparin distal to the balloon through sheath)
- Deflate balloon –
- If bleeding stopped on angio, you are done
- Otherwise have choice:
- Stent if high risk pt and ensure won't cover vertebral (dodgy in subclavian)
- Convert to open with balloon controlling the hole

99. 30 yom, 3 weeks post stabbing in the thigh. Pulsatile thigh mass.

Angio shows distal SFA/prox pop pseudoaneurysm with AVF.

- Approach
 - Open approach vs endo
- Open likely better in distal SFA/pop
 - May use endo balloon for control during repair
 - Covered stent is dicey in pop
- For mid SFA may consider short covered stent.

MESENTERIC ISCHEMIA**100.75 yof, b/l claudication, CMI.**

chronic abdo pain, post prandial pain, weight loss of 20 Lb. Management?

Complete hx and pe
Specifically:

- GI symptoms
- Abdo pain: timing to food intake, how long, progression, aggravating/relieving factors
- Diarrhea, nausea, PUD
- Constitutional: fever/chills/night sweats, appetite/wght loss, sleep/energy
- All about claudication
- RF, RFM, RFtx.
- Meds/all

PE:

- Vs, HR, bruits, LYMPHNODE basins (malignancy), abdo masses, pulses, stigmata of PVD.

All is negative.

- Labs: low alb, pn, chol.
- Invest: duplex to start, CTA, DSA
- G and C scope

Ds: likely CMI and PVD. PVD is stable, no need to intervene, but pt needs visceral angio. It shows occluded SMA origin, Celiac, patent IMA, large meandering a. SMA filled in retrograde fashion.

r/o DD of ACUTE abdo pain:

perf viscus (eso, gastric, duo, sig), pancreatitis, pericarditis, MI, lower lobe pneumonia

What are the non-atherosclerotic causes of chronic mesenteric ischemia?

- FMD
- Aortic dissection
- Aortic coarctation
- Median arcuate syndrome
- Takayasu
- Neurofibromatosis
- Rheumatoid arthritis
- Radiation injury
- Middle aortic syndrome (hypoplasia)
- Buerger's
- SLE
- Drugs – Cocaine, ergot

Mx? Type of procedure?

General statement re: Treatment of mesenteric ischemia:

- In a patient with documented proven chronic mesenteric ischemia (weight loss, postprandial angina, 2 vessels stenosis/occlusion) with otherwise acceptable risk factors for operative intervention, open surgical revascularization provides durable, reliable relief of symptoms.
- Endovascular therapy can be considered for short, non-occlusive focal lesions in patients with significant medical comorbidities.
- Current results of endovascular therapy do not provide comparable durability and reliability of relief from chronic ischemia. However, no good data exists that would compare both modalities.
- It is not clear if endovascular first approach jeopardizes chances of successful surgical re-intervention should PTA fail. Endovascular therapy is in evolution and in the future it may become first line intervention for chronic mesenteric ischemia.
 - Celiac and SMA orificial stenosis tx:
 1. Pta/stent – poor patency rates, poor durability, less symptomatic improvement
 - >80% procedure success, restenosis is high – up to 50%
 - For high risk pts
 - May do for severely malnourished as a bridge to open
 2. Bypass:
 - Op mortality 6%, morbidity – 20%, 5 year patency 78%, survival – 70%
 - Supraceliac:
 - a. Supraceliac aorta less diseased
 - i. More diff to expose than iliac
 - ii. May need to enter chest...
 - b. Supraceliac to CHA/SMA
 - c. Bifurcated Dacron vs Seattle slug off base of celiac
 - i. Long patch angioplasty of the celiac origin with the hood of the graft to the SMA. Hood starts on aorta and ends on the Celiac.
 - d. Retropancreatic tunneling to SMA
 - i. Alternatively, may expose significant portion of SMA above the pancreas, divide SMA and sew end to end to the graft.
 - Iliac/infrarenal aorta:
 - a. Bifurcated
 - b. Easier to expose
 - c. Risk of kinking
 - d. Inflow may be more diseased

- Transaortic endarterectomy:
 - a. Most difficult
 - i. Medial visceral rotation
 - ii. Control supraceliac aorta

Alternative exam scenarios:

Classify mesenteric ischemia, angio appearance of emboli vs acute thrombotic. Conduct of SMA embolectomy. Methods for determining bowel viability intraop.

Three ways to obtain SMA control:

- Above pancreas,
- below pancreas at the root of the mesentery,
- below the mesentery of the small bowel (posterior approach)

For acute thrombosis and ACUTE ischemia:

- Preferred route is the most expeditious and simple
- Use vein, retrograde bypass from infrarenal aorta to the SMA (posterior exposure)

Celiac artery compression syndrome:

- Pt will be fairly well nourished, atypical. Need to exclude psychiatric issues when evaluating their complaints
- Pt (usually female) will have
 - Epigastric pain with nausea (gastric ischemia)
 - Epigastric bruit
 - Pain with food intake
 - Angio – see impingement with EXPIRATION
 - Surgery – release median arcuate lig and explore the artery – transverse arteriotomy, dilate the artery from within or patch...

Very large aside...

Management options for CMI.

Basis of disorder:

- failure to produce intestinal postprandial hyperemia in the pancreatic and small bowel bed (predominantly) due to fixed lesion limitation of the intestinal blood supply.
- Leads to malnutrition and bowel ischemia.

After diagnosis of CMI is entertained, the following questions need to be addressed:

1. Any other conditions that mimic CMI (PUD, hepatobiliary, pancreatitis, cancer)?

To that end, thorough clinical assessment including Hx (postprandial intestinal angina, food fear, weight loss, diarrhea, smoking, female gender, CV RF) and physical exam (cachexia, abdominal bruit, peritoneal signs), Labs (CBC, lactate, ABG, serum albumin, stool free fat, D-xylose), imaging (CT/US) and endoscopy (OGD, colonoscopy) are carried out.

2. Confirmatory studies carried out?

Doppler evaluation by an experienced lab with established criteria are valuable. Peak Systolic velocity of 200 cm/sec (celiac) and 275 cm/sec (SMA) are 80% sensitive for 70% stenosis (EDV >45 cm/sec). If Doppler is positive, then - after appropriate fluid and anti-oxidant optimization of the renal function - a bi-plane angiography is carried out to evaluate:

- celiac, SMA, IMA (particularly on delayed images)
- sequence of filling of individual vessels, branches
- aortic involvement and ostia involvement of renals, celiac, SMA
- distal SMA and celiac branches involvement
- presence of collateral circulation
 - peripancreatic,
 - arc of Riolan at the base of the mesentery
 - Marginal artery of Drummond in the peripheral mesentery
 - L
 - hemorrhoidal plexus
 - internal iliac artery patency

3. Does the pt meet the Indications for intervention?

Symptomatic disease:

All symptomatic pts need to be treated. Traditionally, 2 of the 3 vessels need to be occluded/stenosed prior to symptom development. This is generally true due to the extensive collateral development. In the absence of collateralization, lone >50% stenosis of SMA in the presence of CMI is significant and ought to be revascularized.

However, given significant inherent collateralization of the celiac axis, a lone significant stenosis of the Celiac axis with normal SMA – even with the presence of CMI symptoms – calls diagnosis of CMI in question and deserve further reassessment. Median arcuate

ligament syndrome is diagnosis of exclusion and should be entertained only after other pathology has been ruled out.

Asymptomatic disease:

No RCT or studies of natural history of disease are available to provide meaningful guidelines. Generally asymptomatic disease does not require intervention. It should be kept in mind, though, that in some studies that with asymptomatic patients with 3 vessel disease, 4 out 15 pt with >50% stenosis of all three vessels developed Mes Ischemia within 2.6 years. However, 75 % of pts remained asymptomatic.

Overall, three vessel involvement is a marker of aggressive atherosclerosis associated with significant disease in other vascular beds. In asymptomatic individuals with 2 or 1 vessels disease, no ischemia developed. Even though 15-50% pt with AMI due to thrombosis of pre-existing disease have no antecedent warning signs, **prophylactic revascularization of asymptomatic 3 vessel stenosis cannot be routinely advised.**

If there is need for concurrent aortic aneurysm repair staged reconstruction is recommended. Ideally mesenteric 1st, then aortic. If simultaneous, consider retrograde approach (see below)

4. What type of intervention is advised?

The following options are available:

1. PTA+/-stent
2. trapdoor aortic endarterectomy
3. bypass
4. other (less common – SMA replant onto aorta, SMA-renal bypass)

Goals of intervention:

4. reduce pain
5. prevent bowel ischemia
6. regain weight and restore nutritional reserve
7. prevent recurrence of symptoms

Compared to open revascularization, PTA/S have good immediate technical success (90% vs 100%). *It is noteworthy, that the immediate morbidity and mortality of open and endovascular intervention in several case series are comparable.*

For open repair, 5 year patency (75%), clinical success (85%), survival (70%) were noted. It is suggested, that endovascular results are comparable but few studies provide long-term data. Recent reports from Cambria Group findings suggest that at 1 year primary patency and assisted

patency of endovascular repair was inferior to open technique. Cronenwett group experience reported higher early restenosis and recurrence of symptoms in endovascular group.

In the Cleveland Clinic experience, despite having similar survival in open and endo group, clinical response manifested by durable relief of symptoms at 3 years was better with open interventions (90% vs 65%). *Meta-analysis suggests that open intervention is superior to endovascular approach.*

Data may be skewed by the selection bias with more debilitated pts being relegated to endovascular group.

At present time, **open procedure remains gold standard with respect to achieving lasting clinical response in pts with CMI.** If PTA+/- balloon expandable stent is chosen, then pt should be ready for emergent OR intervention post procedure if endovascular repair fails (due to catastrophic effects of immediate in-stent thrombosis/dissection).

Among open procedures, either *aortic endarterectomy* with visceral vessel ostial clearance or *bypass* are utilized. Both approaches, in experienced hands and with appropriate patient selection yield similar results

AEA success hinges on the “aortic spillover” nature of the mesenteric vessel obstruction. It allows simultaneous revascularization of several visceral ostiae and is not beneficial if there are other than ostial stenosis in SMA or Celiac axis. Patch angioplasty of the vessels’ origin can also be utilized.

Bypass – which is the procedure most commonly performed for CMI - delivers blood flow to the mesenteric circulation by the means of the synthetic (Dacron or PTFE) or biologic (SFV or GSV) graft.

8. What type of bypass is chosen, antegrade vs retrograde?

Generally, antegrade bypass is preferred. Its’ advantages are:

- prograde blood flow
- favorable anatomic circulation
- set up for multiple vessel revascularization
- makes use of fairly uninvolved with atherosclerosis supraceliac/descending thoracic aorta for inflow.

Its’ disadvantage are:

- need for partial or complete supraceliac clamp
- more involved dissection with risk to splenic vein/pancreas injury

Retrograde bypass off the (usually) R common iliac artery (or infrarenal aorta) have the following advantages:

- easier access to the inflow vessel
- faster reconstruction with no need for supraceliac clamping – a bonus in an unstable pt
- usually single vessel reconstruction to SMA is carried out – faster than antegrade

Disadvantages include:

- need for 180 degree reversal of flow for SMA anastomosis - hence risk of graft kinking
- problematic inflow with significant aortoiliac atherosclerotic disease.
- Multiple vessel revascularizations' are more problematic (will require dissection in the lesser sac with issues of graft tunneling)

When compared, both techniques, when done by experts with careful attention to details yield similar results. However, in practice, antegrade bypasses are performed more commonly.

9. What is the choice of conduit – synthetic vs vein?

In the setting of bowel gangrene, autologous conduit material is required (GSV or SFV). In the elective setting, either graft can be used but synthetic is used most commonly. Immediate and short term patency of synthetic vs vein graft were compared and are comparable (89% vs 95%) but at long term (3 year) synthetic grafts appear to have an advantage (85% vs 50%). This results may represent bias in selecting sicker patients with marginal bowel viability (hence, contraindication for synthetic) and low number of patients in several studies.

10. How many vessels need to be revascularized?

In general SMA should be revascularized. It was noted, however, the recurrence rate is improved with multiple vessel reconstructions. Hence, when antegrade bypass is carried out, both celiac (or hepatic/splenic) and SMA are bypassed.

11. What is the timing of intervention and role of TPN?

Enteral nutrition is preferable to TPN but may be difficult to implement due to the nature of the CMI with lack of reactive postprandial intestinal hyperemia. Modification of food composition (less fat) and frequency/size ration (often/small) may allow oral nutrition preop.

TPN does not alter the natural history of CMI and should not delay revascularization as acute mesenteric ischemic crisis can occur while on TPN. TPN related complications (catheter related sepsis, liver dysfunction, bowel mucosal atrophy) should be carefully weighed vs improvement of preoperative nutritional status.

In the postoperative setting, TPN should be used as a part of routine supportive management while multiple organ dysfunction are settling.

12. What are post intervention outcome end-points?

1. Relief of pain
2. symptom recurrence
3. repair durability
4. nutritional improvement

Clinical follow up is important and following resolution of immediate postoperative issues, US surveillance of the graft on a semi-annual basis is instituted to identify impending graft failure.

101.70 yof, CMI, severe SMA/Celiac stenosis. Complication of PTA.

During PTA, dissect and thrombose SMA.

- Management?
- Assess pts stability and sxs
 - AMI vs CMI setting?
 - Work pt up for open if stable
 - If pt has ALI, need to fix this – open repair: bypass
 - Retrograde off aorta

102.55 yom, post mi requiring prolonged CPR. In ICU on pressors. Develops abdo pain.

- Management?
- DD?
 - Non-vascular problems
 - Pancreatitis
 - Acalculous chole
 - PUD
 - diverticulitis
 - Vascular problems
 - Small bowel ischemia
 - Colon ischemia
- Investigations?
 - Review hx and physical
 - If peritonitis – likely needs lap after quick optimization
 - Have family discussion re risk of OR in post MI setting
 - If stable, then work up with CT/angio
- DSA: SMA/cealic occluded. See meandering artery.
- What next?

- May be chronic, assess for other causes
- What is the natural hx of CMI.
 - Depends on whether symptomatic or not:
 - If symptomatic – won't get better with conservative management
 - If asymptomatic – generally stable
 - With all 3 vessels > 50% stenosis
 - in 75% stable, in 25% proceeds to occlusion and symptoms
- Explain surgical approach.
- Name different type of acute mesenteric ischemia.
 - Embolic
 - Thrombotic
 - NOMI
 - Venous thrombosis
 - Acute IMA occlusion syndrome

103.Suspected SMA aneurysm:

Complete H/PE

CT scan abdo

Routine labs, blood cultures, WBC indium scan, DSA –likely SMA aneurysm... Management?

- Rare case
- Likely Mycotic - > 50% in younger pts
- Treatment depends on:
 - Location wrt origin
 - Location wrt entering vessels
 - Shape – saccular, may try embolizing, fusiform – may try stent...

Options:

- Endo: for very sick and anatomically suitable.
 - saccular – may be able to embolize, fusiform – stent across)
- Open:
 - Prep nipples to knees
 - Abx as per ID
 - Transperitoneal approach
 - Mobilize duodenum
 - Isolate SMA at origin, dissect prox and distal to aneurysm
 - Go to lesser sack, transect celiac ganglion, watch for the splenic vein.
 - Trial of clamping SMA

- If no bowel ischemia – ligate proximal to GDA and inferior pancreaticoduodenal branches
- If ischemia – GSV bypass
 - Off infrarenal aorta in acute setting to SMA
 - If totally stable, may try supraceliac which is traditionally used for chronic mesenteric angina setting
- Post op ABX

Expect morbidity and mortality of 10-20%

RENOVASCULAR STUFF.

104.AAA and RAS in 80 yom, well controlled HTN on 3 meds, Cr 130.

Pt has AAA that will be fixed by EVAR. Is there a role for PTA/stent for renal a. in this patient?

No... here's why:

Role of PTA/stent:

- There is no indication to intervene as BP is optimally controlled
- PTA is not durable for renal failure.
- PTA has no effect on survival.
- Restenosis could be up to 37%
 - less with stenting.
 - ASTRAL study is designed to compare PTA vs medical therapy. Preliminary results - Equivalent?
- PTA works best for non-osteal lesions due to FMD.
- May be offered for pts who are at high risk of open surgery.

Results PTA vs surgery: cumulative data from Rutherford

- Same cure for HTN btw surgery and ENDO but 3 time more failure with endo...

- Initial 20% vs 40% improvement in CRF but that does not last for ENDO
 - At 5 years only 25% sustain their renal function
 - 75% get worse OR go on dialysis
 - Compare that to 55% dialysis free stay for 5 year for open surgery
- Open surgery for Renal failure:
 - The worse the failure the better the response to revascularization
 - Creatinine level → Improvement in RF:
 - < 1.8 → 30%
 - >3.0 → 60%
 - For prognostic info to see if there is going to be an improvement in RF post surgery, the most important predictor is the RATE of renal function decline before surgery
- Diabetics may not respond to revascularization

105.60 yom needs open AAA repair, tight bilateral > 80% stenosis, Cr 200. Would I offer surgery for renals?

Would like to know if he is hypertensive.

- If he is, then offer surgery
 - Additionally, Pts has azotemia which strengthens indication for intervention
- If pt has unilateral RAS and high CR but NO HTN, then there is no role for reconstruction.

Aside: **Indications of concomitant aortic and renal reconstruction: p. 1817, 1807**
Asymptomatic pts :

- ***NO role for prophylactic reconstruction.***

Assuming that due to progression of atherosclerosis RV HTN occurs first followed by renal failure

- If we were to take 100 asymptomatic pts
 - expect RV HTN to develop in 44.
- With medical management:
 - out of 44, 16 (36%) will progress to loss of the renal function.
- If these 16 pts are operated upon, 11 (67%) will regain RF,
 - the rest (5 pts) won't.
- **So 5% of pts will be lost if no surgery is offered.**

100-> 44->16->5....

If Surgery was offered at the outset on all 100 pt:

- then expect to have
 - OR mortality of 5.5%,
 - early technical failure of 0.5%
 - late failure in 4% –
- **i.e. a total of 10 pt (%) will be harmed if surgery is done prophylactically.**
- Risk benefit analysis does not support prophylactic repair in asymptomatic pts

Symptomatic patients:

- Unilateral disease:
 - If HTN – if mild, do captopril, if positive – OR
 - If HTN severe – empiric OR
- Bilateral disease:
 - If RAS >80% - empiric OR
 - IF RAS 60-80% - check HTN
 - severe – OR
 - If mild – check CRF –
 - If azotemic - empiric OR,
 - if not – medical therapy

Empiric repair:

- for pts with Hypertension or Hypertension AND CRF
- a causal relationship between RAS and these sequella has not been established

Aside: Renal a. duplex:

- Ideally, would like to interrogate entire renal artery with 60 degree angle corrected Doppler.
 - PSV > 180, RA/Aortic PSV ratio > 3.5 - > 60% stenosis
 - EDV > 150 => 80% stenosis
- Parenchymal angle-independent spot readings. Allow to measure RI, wave shape, AT
- Resistive index
 - Peak systolic frequency shift – PDFS/PSFS
- > 5% difference btw kidneys indicative of > 50% stenosis
- RI > 80% - highly unlikely to benefit from surgery or revascularization
 - Seen in intrarenal vessel disease
 - Seen in subcapsular collection
 - Seen in low CO

- Tarda and parva waveforms
 - acceleration time > 0.07 sec
 - acceleration time index >3 m/sec²

Surgical causes of hypertension:

- RAS
- Aortic coarctation
- Pheochromocytoma
- Conn's
- Cushing's

Causes of RV hypertension:

- RAS
 - Atherosclerosis
 - Congenital – bands/webs
 - FMD
- Embolism, leading to parenchymal disease:
 - Heart
 - Aortic atherosclerosis
 - Aortic aneurysm
 - Renal artery
 - Renal aneurysm
- Dissection
 - Aortic
 - renal
- AVM
- Trauma
- Weird & Wonderful
 - Vasculitis:
 - Takayasu
 - PAN
 - Neurofibromatosis
 - Necrotizing Angiitis
 - Post surgery:
 - Post bypass stenosis
 - Post transplant stenosis

It is difficult to distinguish early ischemic nephropathy (may be reversible) from chronic parenchymal medical disease (not reversible).

Unilateral stenosis leads to overproduction of renin which – through Angiotensin II, drives pressure up, remodels CVS, retains Na, and may have direct toxic effect on tubular elements of kidney. This effect is counteracted by contralateral normal kidney with natriuresis.

Bilateral RAS leads to hyperaldosteronism, hypervolemia, and then sustained adaptation of the CVS to higher pressures. New set point is reached for expanded effective circulating volume. Renin will be suppressed but HTN persists due to hypervolemia and adaptive CVS changes persist.

In the end, hypervolemia, vascular hypertrophy and vascular reactivity sets in.

Surgical options:

- Aortorenal bypass
 - a. GSV
 - b. 6mm prosthetic
 - c. Hypogastric a. in kids
- Thromboendarterectomy
 - a. Transrenal
 - b. Transaortic
- Splanchnorenal bypass: have to ensure celiac artery patency
 - a. Hepatorenal
 - i. Relatively easy
 - b. Splenorenal
 - i. Much more difficult proposition
- Re-implantation
- Ex-vivo reconstruction: indications
 - a. When reconstruction > 45 min
 - b. All lesions involving branches (RAA, stenosis, AVM, dissection)
 - c. Failure of prior reconstruction
- Endo: PTA/stent
 - Ideal for FMD (medial fibroplasias type)
 - Primarily for HTN treatment,
 - not effective for CRF long term
- Nephrectomy – only if kidney is non-functional AND disease is non-reconstructable
 - Why?
 - a. Equivalent blood pressure response with revascularization and nephrectomy
 - b. Improved renal function after revascularization confers a survival advantage.

Surgical Approach to renal arteries:

- Midline or Transverse incision
 - Advantage of transverse - handle instruments perpendicular to longitudinal axis of the body
 - Supraumbelical
 - Mid axil->mid clavicular
- R renal:
 - R medial rotation of colon and Kocherization of duo/panc head
 - Disect middle of R renal a. first
 - If start distally - troublesome bleeding
 - Retract R renal vein cephalad
 - May need to ligate adrenal/small branches
 - Disect osteum
 - Ligate lumbar veins
 - Push IVC laterally
- L renal:
 - L medial rotation: better than transmesenteric
 - Ligate L gonadal and adrenal vein
 - Retract L renal vein cephalad
- Aorta is dissected for 5 cm infrarenally
- Fluid load and give 12.5 g of manitol before clamping
- GSV graft – spatulate branched portion and anastomose it to aorta first
- Tunnel R graft retrocaval, L graft behind R renal vein

ASIDE:

Appropriate investigations for RV HTN

Clinical information that raises suspicion and prompts further Laboratory and Anatomical/Functional Studies:

- rapid onset of HTN in young
- rapid deterioration of previously well controlled HTN
- hypertensive crisis
- 3-drug resistant HTN
- HTN and deteriorating renal function
- Renal function deterioration when starting ACE inhibitors
- Abdominal, flank, back bruit

Several preliminary laboratory studies...

- Cr and GFR – to evaluate baseline renal function
- Studies designed to r/o mimicking conditions

- i. K – to r/o aldesteronism
- ii. 24 h urine cortisol – to r/o hypercortisolism
- iii. Urine metanephrine to r/o pheo

... as well as ECG (to assess for L ventricular strain and hypertrophy) are carried out but do not provide information regarding the presence of RAS or contribution of RAS to hypertension.

After diagnosis of RAS, the most difficult task is to establish the causal relationship between hypertension and RAS.

Step one - Anatomic imaging: provides images of renal artery and hemodynamic data

Angiogram – provides morphological picture. Modality of choice for Fibromuscular disease as it will pick multiple distal lesions as well accessory/polar renal arteries. However, it does not indicate or help to decide whether intervention is warranted. RAS is prevalent in pts with HTN but presence of stenosis does not suggest causal relationship. 15mm Hg gradient may suggest that stenosis is of functional importance. Contrast load may contribute to renal dysfunction.

MRA vs CT in renal artery imaging...

	CT	MRA
Ability to discriminate btw calcifications	-	++
Stent visualization	++	-
Negative predictive value	++	+++ , almost 100%
Tendency to overestimate lesion's severity	+	++
FMD detection	++	-
Branches of polar artery detection	-	++

Doppler US: non-invasive by operator dependent.

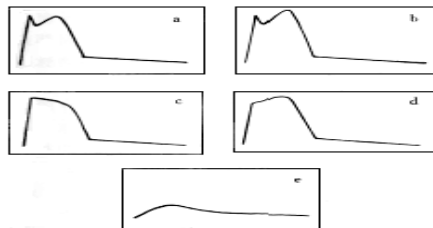
Interrogation of the entire renal a. The following factors were found to be significantly predictive of 60% “angiographic” RAS:

5. Ratio of Peak Systolic velocity in the RA to the peak systolic velocity in the adjacent aorta 3.5:1
6. Peak Systolic velocity in the RA 180-200 cm/sec plus post stenotic turbulence.
7. EDV of 150 cm/sec may correspond to 80% stenosis.

Sensitivity (93%) and specificity (98%) were noted in single renal artery kidneys. However, sensitivity is diminished when polar or accessory renal arteries are encountered. These studies are labor intensive and cannot be replicated by all operators. Hence, simplified methods can be utilized.

Indirect Doppler evaluation of waveforms of the distal renal arterial tree: segmental waveforms are obtained at the hilum, upper, middle and lower poles. This does not indicate exact location of the lesion.

Tardus wave (e) form denotes high grade proximal RAS. Hemodynamic significance of this stenosis is further established by evaluation of acceleration time, acceleration index and wave-form pattern recognition. This simplifies the process and allows faster, easier yet reasonable accurate assessment.



Resistive index: an estimate of renal arterial resistance. The higher the index, the more likely the kidney is affected by severe underlying nephrosclerosis and glomerulosclerosis. Initially used to determine presence of RAS (fairly non-specific – goes up with medical renal disease, decreased CO, perinephric fluid collections), it is more useful as predictor or response to successful revascularization. With RI > 0.8, pts were highly unlikely to benefit from surgery or angioplasty.

Note, the duplex has high negative predictive value in determining if renal artery is the cause for Renal failure: i.e. if Renal scan is normal, chances are RF is due to parenchymal disease

However, in looking for source of Hypertension, duplex can't pick up polar arteries. So even if Renal artery is normal, duplex can't rule out polar artery anatomy or stenosis.

Functional imaging: relies on renin-angiotensin axis. Test was designed to provide meaningful data on functional significance of RAS but overall they have high degree of false-negative results.

Renal Vein Renin Assay (RVRA:)

This test can be used to study functional significance of RAS. Pts with RVH and unilateral RS demonstrate hypersecretion of renin from the ischemic kidney and suppression from the normal one. 90% of these pts will benefit from revascularization. However, apart from not being widely available and invasive, this test is unhelpful for bilateral RAS, which is found in many patients. Up to 57% of non-lateralizing RVRA were found to benefit from the intervention. Not done routinely.

Captopril provocative radionuclide testing:

Stop Beta Blockers, ACEI before hand, load with salt. GFR in kidney with RAS depends to a great degree on the presence of Angiotensin II (which is present there in supranormal concentration due to hypoperfusion of the kidney. ATII constricts efferent (exit) arteriole and increase perfusion pressure in the glomerulus.

At first, Baseline radioisotope scan is carried out. Administration of Captopril (25-50 mg). This, in RAS affected kidney, will inhibit Angiotensin Enzyme and slow down conversion to ATII. This will cause reduction of ATII mediated vasoconstriction of Efferent arteriole thus decreasing GFR in that kidney. Overall excretion of radioisotope will be reduced with marked cortical retention compared to baseline.

Test has adequate negative predictive value to rule out unilateral RAS. If renal function is preserved, a positive study has 88% positive predictive value. However, captopril scanning is less reliable with significant renal impairment and bilateral RAS. In practice, Captopril scanning is done infrequently.

This leads to great degree of uncertainty regarding functional significance of RAS. The only absolutely certain way to define relationship of RAS in HTN or ischemic nephropathy is to observe the beneficial effect of an intervention.

106.70 yom, smoker, HTN, on bblockers, Cr 150, 7 cm juxtarenal AAA.

- Preop work up
 - AAA wise:
 - May need angio to visualize visceral and renal a, outflow
 - AAA needs repair
 - Smoker, COPD, HTN – risk of rupture...
 - Size wise
 - Optimize preop –
 - functional level, longevity assessment, cardio/anesthesia
 - Classify his Lee criteria
 - Heart problems
 - CHF
 - DM (insulin)
 - Aortic procedure
 - Cr > 180
- Literature support for preop cardiac testing
 - CARP study – unless clinically indicated, no need for revascularization
 - Courage study – PCI=medical therapy, need PCI preop??
 - If clinical suspicion, needs non-invasive (MUGA)
 - See preop in Minimus
- See incidental calcification of the L renal a, approach. Would you do DSA?
 - Renal wise:
 - Symptomatic vs asymptomatic?
 - If asymptomatic, leave alone...
 - Bilateral vs unilateral stenosis ?
 - Measure RI
 - If severe stensis bilaterally, presence of HTN, Risk factors, and RI <0.8, consider revascularization
 - Otherwise, medical management
- What further work up would you do if any?
 - Angio may be useful
 - Captopril testing not helpful here (high Cr)
 - Any decision to do renal re-vascularizaion for bilateral RAS should be on clinical and empiric basis only.

107.70 yom, good cardiac risk, 8 cm AAA, CR 160, poorly controlled HTN on 3 drugs.

- Approach?
- Indications for preop angio?

- Angio shows bilateral 99% stenosis well away from the orifice (i.e. not ostial)
- How do you repair these lesions?
 - Likely atherosclerotic
 - Pt is symptomatic
 - Needs open repair – via bypass
 - Fix aneurysm first
 - Bypass off the tube graft

108. 80 yom, 2 antihypertensives, Cr 95, previous MI, stable angina. 6.5 cm AAA with RAS R renal a. occlusion (good distal vessel on nephrogram) and severe L distal artery stenosis 95%.

- Management?
 - Pt is asymptomatic (adequate blood pressure control on 2 meds)
 - Has good collateralization to R kidney
 - Despite stenosis, stil has good renal function
 - Plan: repair AAA only

109. 80 yom, severe HTN on 3 drugs, difficult to control, 7 cm infrarenal AAA, Cr 300

- Approach to treatment?
- Angio – severe RAS bilaterally
- Plan – fix RAS (bypass) off the AAA graft
- Reservation re: recovery of renal function if Resistive index > 0.8

110. Angio of renal a. aneurysm: distal, near the first branching, asymptomatic pt.

- Assess indications for intervention
- Pt may require ex-vivo reconstruction

Aside:

Indications for repair:

- Symptomatic
 - Rupture (calcification not protective)
 - pain
 - Embolisation leading to HTN, CRF
 - Hematuria
 - Collecting duct obstruction

- acute dissection threatening kidney viability
- any size in women of Child bearing age & pregnant
 - OSLER suggests watchful waiting for last trimester, repair in the first.
- > 3-4 cm in asymptomatic

Natural hx

- 3% rupture, 80% have htn

Management options:

1. Repair with interposition graft
2. Ex-vivo repair with autogenous vein reconstruction
3. Prox/distal ligation with aortorenal/hepatorenal/splenorenal bypass
4. Nephrectomy along with aneurysm
5. Transcatheter embolization of saccular aneurysm or stent

Indications for Ex-vivo reconstruction:

- a. When reconstruction > 45 min
- b. All lesions involving branches (RAA, stenosis, AVM, dissection)
- c. Failure of prior reconstruction

110.56 year old female, with HTN. Work-up shows 2.5 cm renal artery aneurysm.

- What is the differential for RA aneurysms?
 - FMD, atherosclerosis, Behcet, PAN
- Would you suggest repair?
 - yes, young patient, now comorbidities, hypertension.
- Management:
 - Work up for HTN
 - Split renin function to see if aneurysm is causing hypertension.
 - RI measurement
- If can attribute HTN to aneurysm, take it out.

111.45 yr old female with uncontrolled HTN. Approach.

- Typical findings of FMD on angio.
- What other arteries affected?
- Cause of FMD?
- Management options?

112.20 yom with difficult to control HTN. 3 medications.

- What is the differential for HTN?
- Worked up by nephrologist, found to have coarctation. Large intercostals seen.
- What is the pathophysiology of HTN with coarctation?
 - Same mechanism as bilateral RAS, with no lateralizing features, low renin, volume dependent HTN.
- How would you repair
 - refer to cardiac surgeon to repair
- PTA an option?
 - High risk of rupture, unless prepared to PTA with stent but that would cover intercostals.
- Decided on open:
 - approach similar to TAAA,
 - explain risks
 - surgical ways to maintain spinal perfusion ie. passive/active shunts.
- What if pt has right renal artery stenosis to the primary branches.?
 - Pt has HTN, if normal Cr, may try functional studies but we already have an indication.
 - Open repair is indicated, not PTA
 - surgical approach to renal arteries
 - what conduit I would use
 - in a child, use iliac artery, if adult - GSV

